



Research Article

Dimensions and Post-Treatment Changes of Anterior Dentoalveolar Bone in Female Orthodontic Patients with Different Vertical Skeletal Patterns

Niwat Anuwongnukroh¹, Surachai Dechkunakorn², Hatairat Vitthayanon³ and Suleekorn Krailassiri⁴

^{1,2}Department of Orthodontics, Faculty of Dentistry, Mahidol University, Bangkok, Thailand

³Private Practice, Bangkok, Thailand

⁴Dental Unit, Phanangkao Hospital

Correspondence should be addressed to: Niwat Anuwongnukroh; niwat.anu@mahidol.ac.th

Received date: 4 June 2013; Accepted date: 25 September 2013; Published date: 29 November 2013

Academic Editor: Teruko Takano-Yamamoto

Copyright © 2013. Niwat Anuwongnukroh, Surachai Dechkunakorn, Hatairat Vitthayanon and Suleekorn Krailassiri. Distributed under Creative Commons CC-BY 3.0

Abstract

Objective: To determine the maxillary and mandibular anterior dentoalveolar bone width, height and length (MxAW, MdAW, MxAH, MdAH, MxAL, and MdAL) in Thai female patients with skeletal open bite, normal bite and deep bite and to compare the differences in these dimensions after fixed orthodontic treatment. **Materials and Methods:** A total of 116 pairs of pre-orthodontic treatment (T1) and post-orthodontic treatment (T2) lateral cephalograms of female patients (mean age 19.16 years) were selected systematically from the department database and digitized using a customized cephalometric software program (Dentofacial planner version 5.32). Analysis of variance (ANOVA) and Scheffe's test were used to assess the differences among vertical skeletal groups at the 95% level of confidence ($P < 0.05$). To determine the differences between pre-treatment and post-treatment dimensions, paired t-test was performed. **Results:** Significant differences were found among vertical skeletal groups in all anterior dentoalveolar dimensions ($P < .05$). MxAW and MdAW in open bite group were significantly smaller than those of normal bite and deep bite groups but MxAH, MxAL, MdAH and MdAL of open bite group were significantly longer than those of other groups. However, Scheffe's test indicated no significant difference in dimensions between normal bite and deep bite groups ($p > .05$). All post-treatment dimensions, except MxAH, significantly decreased in open bite group, but only MxAL, MdAH and MdAL decreased significantly in deep bite group after treatment. **Conclusion:** All anterior dentoalveolar dimensions were significantly different among skeletal vertical groups. The anterior dentoalveolar dimensions were significantly decreased after orthodontic treatment in all vertical groups, except MxAH.

Keywords: Anterior dentoalveolar dimensions, vertical skeletal patterns, orthodontic treatment

Introduction

Orthodontists have long been interested in the multitude of differences in the diagnosis, treatment, and treatment response between skeletal open bite and skeletal deep bite. These two distinct types of facial form have been characterized in the literature as "hyperdivergent" (Sassouni, 1962; Shudy, 1964) or "long face syndrome" (Schendel et al., 1976) and "hypodivergent" (Sassouni, 1962; Shudy, 1964) or "short face syndrome" (Opdebeeck and Bell, 1978).

Most orthodontic studies have reported on craniofacial structures, but only a few studies focused directly on the dentoalveolar characteristics and their treatment changes. Dechkunakorn et al., (1994) reported the assessment of facial heights and dentoalveolar heights in Thai individuals with normal occlusion. No study has yet focused on the anterior dentoalveolar characteristics especially the post-treatment changes of anterior alveolus in vertical skeletal patterns in the Thai population. Therefore, the purposes of this study were to determine and compare the significant differences of the maxillary and mandibular anterior dentoalveolar bone width, height and length among skeletal open bite, normal bite and deep bite in Thai female subjects, and to determine the changes of these dimensions after tooth movement with conventional fixed orthodontic treatment in these three vertical groups. The hypothesis of the study was that there were no differences in dimensions and post-treatment changes of anterior dentoalveolar bone in female orthodontic patients with different vertical skeletal patterns.

Materials and Methods

A total of 116 pairs of pre-treatment and post-treatment lateral cephalometric radiographs of Thai female subjects were obtained from the patient database of the Department of Orthodontics, Faculty of Dentistry, Mahidol University.

The average age of the subjects was 19.16 ± 2.82 years. The age of the subjects ranged from 16 to 27 years old. All subjects were

identified as craniofacial growth-ceased patients, aged older than 16 by pre-treatment radiographs. No obvious craniofacial deformities, systemic diseases or other factors affected craniofacial growth and development. All permanent teeth were present before orthodontic treatment, except the upper and lower third molars. No restorations were involved the incisal edges of upper and lower central incisors. All subjects had pre-treatment and post-treatment lateral cephalographs and were treated with the edgewise-fixed orthodontic appliances with extraction of the four first bicuspids.

The subjects were divided into three groups according to vertical skeletal pattern. Numbers of subjects in skeletal open bite, normal bite, and deep bite were 42, 65, and 9, respectively. The SN-MP angle was used for vertical skeletal assessment. From the study of Dechkunakorn et al., (1994), the mean SN-MP angle of Thai female norm was 32.94 ± 5.62 degrees. In this study, therefore, one standard deviation above and below the norm was used to define the skeletal open bite (SN-MP > 38.56 degree) and skeletal deep bite (SN-MP < 27.32 degree), respectively.

Cephalometric Analysis

The method for measuring the maxillary and mandibular anterior dentoalveolar width, height, and length in pre-treatment and post-treatment lateral cephalometric radiographs is described in Figure 1. To study the post-treatment change, constructed distances (H1, H2, H3) from the reference planes (palatal plane, mandibular plane) perpendicular to the level of upper incisor apex, subspinale, and lower incisor apex were measured and transferred from the pre-treatment film to the post-treatment film (Figure 2). Thus, the resorption of the root apex of incisors and the remodeling of subspinale from incisor retraction after orthodontic treatment would not affect the study measurements. Because different x-ray machines were used in the Department of Orthodontics, the difference of magnification between pre-treatment and post-treatment film was calibrated by

calculating the proportion of pre-treatment and post-treatment of nasion and sella distances (SN), which remains unchanged

in young adult patients, as seen in the following equation.

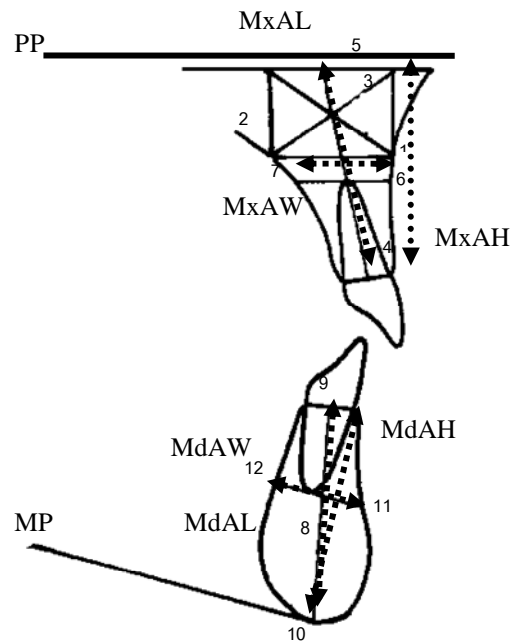


Figure 1: Illustrations of anterior dentoalveolar landmarks and measurements used in the study

Landmarks: 1 = A-point, 2 = palatal counterpart of A point on palatal cortical bone at the same distance from the palatal plane as A point, 3 = center of rectangular limited by line 1-2 and palatal plane. The rectangle represents the midsagittal section of basal bone of maxilla. This point was defined as the center point of maxillary alveolus (Beckmann et al.,1998), 4 = midpoint of alveolar meatus of maxillary central incisor, 5 = intersection between palatal plane and maxillary alveolar axis (maxillary alveolar axis runs from midpoint of alveolar meatus of maxillary central incisor through center point of maxillary alveolus), 6 & 7 = frontal and dorsal point of the line that drawn from labial cortical plate through the apex of upper central incisor and parallel to the palatal plane to the palatal cortical plate, 8 = center point of basal midsagittal bone of mandible (point D), 9 = midpoint of alveolar meatus of mandibular central incisor, 10 = intersection between symphyseal surface and mandibular alveolar axis (mandibular alveolar axis runs from midpoint of alveolar meatus of mandibular central incisor through point

D), 11 & 12 = frontal and dorsal point of the line drawn from the labial cortical plate through the apex of the mandibular central incisor and parallel to the mandibular plane to the lingual cortical plate of symphysis. Maxillary anterior dentoalveolar width (MxAW) = the distance from point 6 to 7; maxillary anterior dentoalveolar height (MxAH) = the distance from Pr to palatal plane and perpendicular to the palatal plane; maxillary anterior dentoalveolar length (MxAL) = the distance from point 4 to 5; mandibular anterior dentoalveolar width (MdAW) = the distance from point 11 to 12; mandibular anterior dentoalveolar height (MdAH) = the distance from Id to mandibular plane and perpendicular to the mandibular plane, and mandibular anterior dentoalveolar length (MdAL) = the distance from point 9 to 10.

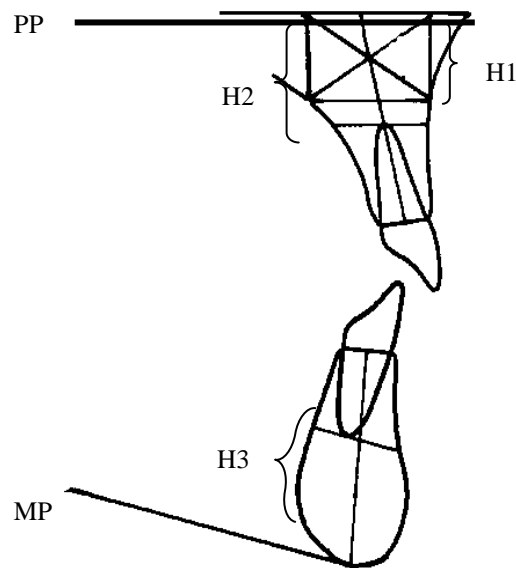


Figure 2: Reference distances from pre-treatment film to post-treatment film

H1 = the perpendicular distance from the palatal plane to subspinale; H2 = the perpendicular distance from the palatal plane to the plane that parallels the palatal plane passing the root apex of the upper incisor, and H3 = the perpendicular distance from the mandibular plane to the plane that parallels the mandibular plane passing the root apex of the lower incisor

$\frac{SN(T1)}{SN(T2)}$ X Dimensions measured in T2 = Dimension measured in T2 with the same SN(T2) magnification as T1.

Each cephalometric radiograph was traced and digitized by a single examiner and was confirmed by two experienced orthodontists.

Statistical Analysis

All statistical calculations were performed with SPSS for Windows version 10.0. One-way analysis of variance (ANOVA) was performed to assess differences occurring among the groups and Scheffe's test was used to identify which pair of groups was significantly different. Paired t-test was used to determine differences between pre-treatment and post-treatment anterior

dentoalveolar dimensions in each subgroup.

To determine the reliability of measurements, ten pairs of pre-treatment and post-treatment radiographs were randomly selected for a second evaluation after a three-week interval. Paired t-test was carried out on the mean differences between the first and the second measurements. No statistically significant differences ($P > .05$) were found in all measurements.

Results

The means, standard deviations and the significant differences of the anterior dentoalveolar dimensions among vertical skeleton pattern groups are presented in Table 1. The means and standard deviations of pre-treatment and post-treatment anterior dentoalveolar dimensions in skeletal open bite, normal bite and deep bite are presented in Tables 2, 3, and 4, respectively. The positive or negative changes in the values indicate increase or decrease of dimensions after treatment.

Table 1: Means, standard deviations and significant differences of anterior dentoalveolar dimensions(millimeters) among vertical skeletal patterns of female subjects

Variables	Skeletal open bite (n=42)		Skeletal normal bite (n=65)		Skeletal deep bite (n=9)		P value
	Mean	SD	Mean	SD	Mean	SD	
Maxillary							
MxAW	14.08	2.71	15.49	2.69	16.89	2.92	< 0.01
MxAH	19.89	2.28	18.09	2.17	16.36	2.79	< 0.001
MxAL	26.30	2.89	24.77	2.70	23.76	2.90	< 0.01
Mandibular							
MdAW	8.12	1.25	9.16	1.42	10.11	1.72	< 0.001
MdAH	35.99	3.12	33.50	2.31	32.50	2.31	< 0.001
MdAL	36.72	3.14	34.19	2.35	33.26	2.43	< 0.001

Comparison of the Anterior Dentoalveolar Dimensions Among Skeletal Open Bite, Normal Bite and Deep Bite Groups.

From Table 1, the analysis of variance showed that all maxillary and mandibular anterior dentoalveolar dimensions were significantly different among vertical skeletal patterns. Moreover, Scheffe's test showed significant differences between skeletal open bite and skeletal normal bite and between skeletal open bite and skeletal deep bite groups. The alveolar width of the skeletal open bite group (MxAW 14.08±2.71mm., MdAW 8.12±1.25mm.) was narrower than normal bite (MxAW 15.49±2.69mm., MdAW 9.16±1.42mm.) and deep bite groups (MxAW 16.89±2.92mm., MdAW 10.11±1.72mm.). The alveolar height and length of the skeletal open bite group (MxAH 19.89±2.28mm., MdAH 35.99±3.12mm., MxAL 26.30±2.89mm., MdAL 36.72±3.14mm.) were longer than normal

bite (MxAH 18.09±2.17mm., MdAH 33.50±2.31mm., MxAL 24.77±2.70mm., MdAL 34.19±2.35mm.) and deep bite groups (MxAH 16.36±2.79mm., MdAH 32.50±2.31mm., MxAL 23.76±2.90mm., MdAL 33.26±2.43mm.). The alveolar width of the skeletal deep bite group was the widest and the alveolar height and length were shortest, with no statistical difference between skeletal deep bite and skeletal normal bite groups ($P>.05$).

Comparison of Pre-Treatment and Post-Treatment Variables in Each Subgroup Skeletal Open Bite (Table 2)

All anterior alveolar variables were significantly different between pre-treatment and post-treatment. Most anterior dentoalveolar dimensions significantly decreased after orthodontic treatment except MxAH, which significantly increased after treatment.

Table 2: Means, standard deviations, and significant differences between pre-treatment and post-treatment anterior dentoalveolar dimensions(millimeters) in skeletal open bite female subjects (n=42)

Variables	Pre-treatment		Post-treatment		Post-Pre	SD	P value
	Mean	SD	Mean	SD			
Maxillary							
MxAW	14.08	2.71	13.34	2.62	-0.74	1.96	< 0.05
MxAH	19.89	2.28	20.50	2.71	0.61	1.43	< 0.01
MxAL	26.30	2.89	24.07	2.96	-2.23	2.25	< 0.001
Mandibular							
MdAW	8.12	1.25	7.76	1.35	-0.36	0.92	< 0.05
MdAH	35.99	3.12	35.10	3.17	-0.89	1.98	< 0.01
MdAL	36.72	3.14	35.88	3.01	-0.85	1.50	< 0.01

Skeletal Normal Bite (Table 3)

Only MxAW was not significantly different between pre-treatment and post-treatment ($P>.05$). Other dimensions changed similar

to the open bite group. MxAH significantly increased ($P<.001$) whereas MxAL, MdAW, MdAH, and MdAL significantly decreased after orthodontic treatment ($P<.001$).

Table 3: Means, standard deviations, and significant differences between pre-treatment and post-treatment anterior dentoalveolar dimensions(millimeters) in skeletal normal bite female subjects (n=65)

Variables	Pre-treatment		Post-treatment		Post-Pre	SD	P value
	Mean	SD	Mean	SD			
Maxillary							
MxAW	15.49	2.69	15.28	2.94	-0.25	1.52	0.281
MxAH	18.09	2.17	18.92	2.38	0.83	1.49	<0.001
MxAL	24.77	2.70	22.78	2.67	-1.99	2.11	<0.001
Mandibular							
MdAW	9.16	1.42	8.69	1.45	-0.47	0.83	<0.001
MdAH	33.50	2.31	32.19	2.73	-1.31	1.43	<0.001
MdAL	34.19	2.35	32.93	2.64	-1.25	1.29	<0.001

Skeletal Deep Bite (Table 4)

Paired t-test showed that MxAL, MdAH, and MdAL from post-treatment cephalograms

significantly decreased ($P<.01$, $.05$, and $.01$, respectively). MxAW, MxAH, and MdAW were not significantly different between pre-treatment and post-treatment ($P>.05$).

Table 4: Means, standard deviations, and significant differences between pre-treatment and post-treatment anterior dentoalveolar dimensions(millimeters) in skeletal deep bite female subjects (n=9)

Variables	Pre-treatment		Post-treatment		Post-Pre	SD	P value
	Mean	SD	Mean	SD			
Maxillary							
MxAW	16.89	3.92	16.36	3.40	-0.53	0.73	0.060
MxAH	16.36	2.79	16.14	3.16	-0.22	1.10	0.567
MxAL	23.76	2.90	21.07	2.14	-2.69	2.30	<0.01
Mandibular							
MdAW	10.11	1.72	9.64	1.75	-0.49	0.62	0.054
MdAH	32.50	2.31	30.81	2.89	-1.69	2.00	<0.05
MdAL	33.26	2.43	31.37	2.74	-1.88	1.62	<0.01

Discussion

This study was designed as a retrospective study to identify significant differences in the maxillary and mandibular anterior dentoalveolar width, height, and length among skeletal open bite, normal bite, and deep bite subjects. Post-treatment changes were also evaluated to emphasize the care that must be taken during orthodontic treatment. The purpose of extraction in this sample group was to relieve crowding and/or anterior teeth proclination.

The differences of the maxillary and mandibular anterior dentoalveolar width, height, and length among vertical skeletal patterns

In this study, the method for measuring the anterior dentoalveolar width was modified from that of Beckmann et. al.,(1998) so that post-treatment changes could be compared to pre-treatment changes.

The width of the anterior dentoalveolus was significantly different among vertical

skeletal groups. This measurement in the skeletal deep bite group was significantly greater than normal bite and open bite groups. The anterior dentoalveolar width in the skeletal open bite group was the narrowest. Similar results were found in the studies of Handelman(1996), Beckmann et. al., (1998), and Wonglamsam et. al., (2003).

In contrast, Edwards(1976) found no statistically significant correlation between the labio-lingual width of the anterior portion of the palate and “high-” or “low-SNMP angle” cases. A wide variation of width existed in all SNMP groups.

For the anterior dentoalveolar height, most studies measured the anterior dental height from the incisal edge perpendicular to the palatal plane and mandibular plane (Schendel, et al.,1976; Isaacson, et al.,1971; Richardson,1970). The means of maxillary and mandibular anterior dental height were, therefore, larger than the anterior dentoalveolar height in this study. In this study, the anterior dentoalveolar heights were measured along the lines perpendicular to the palatal plane and mandibular plane and measured from Prosthion in the maxilla and from Infradentale in the mandible. Therefore, the measurements in the present study reported the absolute anterior dentoalveolar height, not including the crown height, which may also vary between individuals.

The result of this study showed that the significantly greatest value of anterior dentoalveolar height was found in the skeletal open bite group and the lowest value in the skeletal deep bite group. This result was in agreement with many previous studies(Shudy,1964; Schendel,et al.,1976; Isaacson,et al.,1971; Opdebeeck, et al.,1978). The result was also inconsistent with Handelman(1996), who found the anterior alveolar height above the maxillary incisors and below the mandibular incisors in the high angle group was larger than the low angle group.

For the anterior dentoalveolar length, the measurement method used in this study was the same as that of Beckmann et.

al.,(1998). The result of the present study also supported the findings of Beckmann et. al.,(1998) in that the maxillary anterior dentoalveolar length showed the significantly greatest value in the skeletal open bite group and the lowest in the skeletal deep bite group.

These findings of increased anterior dentoalveolar length and height confirmed the result of Betzenger and Pancherz(1999) that the cause of open bite in the skeletal open bite group was not due to an underdevelopment of the dentoalveolus in this area, but rather that an adaptation may have occurred in an attempt to compensate for the vertical skeletal discrepancy by overeruption of the incisors. The oral habits seem to have an impact on both the skeletal morphology and the compensatory mechanism. In addition, the greatest values of anterior mandibular dentoalveolar length and height also supported Shudy's study(1964) that the mandibular incisors were the greatest compensator in the skeletal open bite group and the anterior dentoalveolar process tried to compensate for the lack of harmony between posterior alveolar growth and ramus growth.

Handelman(1996) also found that what appears to be a direct relationship between increased facial and alveolar height and thinning of the alveolar bone. Apparently, as a consequence of facial height increase, the incisors erupt to maintain the overbite, and the alveolus becomes attenuated with a thinning of the width between labial and lingual walls. Beckmann et. al.,(1998) suggested that the increase in height of symphysis seems to coincide more with a narrowing of its shape. Consequently, the possibilities of labiolingual movement of the mandibular incisors in long-faced subjects are limited.

Kraus et. al.,(1959) concluded that the lower anterior facial height is largely determined by heredity. Beckmann et. al.,(1998) found that the lower anterior facial height and the mandibular alveolar and basal shape seem to be related. It is possible that the shape of the frontal alveolar and basal bones is also at least partially influenced by the same genetic

factors that determine the lower facial height. This same factor also had an influence on the shape of symphysis.

Table 5 shows that the maxillary and mandibular anterior dentoalveolar width of Thai female subjects in this study was wider than that of Caucasian subjects in

other studies. In addition, the anterior dentoalveolar length of all vertical skeletal patterns in this study was also longer than that of White European female subjects in a study by Beckmann et al.,(1998). This showed that the configuration of the facial skeleton is also determined by racial or ethnic group.

Table 5: Width of maxillary (Mx) and mandibular (Md) anterior dentoalveolus from previous studies and this study (millimeters)

Studies		Open bite	Normal bite	Deep bite
Handelman, 1996 (White, Male & Female)	Mx:	12.0±2.4	12.7±2.3	14.7±2.9
	Md:	5.5±1.8	7.0±2.2	8.7±1.9
Beckmann et al., 1998 (White European Male)	Mx:	12.01±3.27	13.30±3.00	12.52±2.94
	Md:	6.60±1.95	7.79±1.91	8.50±1.61
Beckmann et al., 1998 (Female)	Mx:	10.57±1.95	11.65±2.85	13.01±2.25
	Md:	7.02±1.88	7.85±1.82	9.74±2.03
This study (Thai Female)	Mx:	14.08±2.71	15.49±2.69	16.89±2.92
	Md:	8.12±1.25	9.16±1.42	10.11±1.72

The Post-Treatment Changes of the Anterior Dentoalveolar Width, Height, and Length in Skeletal Open Bite, Normal Bite, and Deep Bite Subjects.

In this study, when comparing the treatment changes of anterior dentoalveolar dimensions in skeletal open bite, normal bite, and deep bite (Tables 2-4, respectively), it was found that there was a significant statistically difference in anterior dentoalveolar dimension between pre-treatment and post-treatment in each skeletal pattern group. This result revealed that orthodontic tooth movement has some influence in the change related to anterior dentoalveolar dimension. In this study, MxAW and MdAW in the skeletal open bite group, and MdAW in the skeletal normal bite group significantly decreased. Although it is agreed that orthodontic tooth movement can remodel alveolar socket; anatomical limits set by the cortical plate of the alveolus may be regarded as orthodontic walls. The attempt to move teeth against these walls could cause apical root resorption, alveolar bone loss, and bone fenestration as found in many studies(Wainwright,1973; Ten Hove and Mulie,1976; Wehrbein et al.,1996; Mulie and Ten Hove,1976; Ten Hove et al.,1977). However, these changes were

small. The possible explanation could be that in this study arch width was measured at the root apex, which was subjected to change less than that at the marginal and mid-root area of the alveolus(Sarikaya et al.,2002). Nevertheless, in cases which exhibited apical root resorption, the measured alveolar bone width underwent more changes. The width of maxillary and mandibular anterior alveolus was not significantly changed in the skeletal deep bite group. The wider anterior dentoalveolar width in the skeletal deep bite group creates a large area to accommodate the anterior retraction, so the retraction would not disturb the palatal or lingual cortex of maxillary and mandibular alveolus.

In skeletal open bite and normal bite groups, MxAH was the only variable that significantly increased after treatment. The extrusion of upper incisor during retraction and uncontrolled tipping type of tooth movement could explain this result. In skeletal deep bite group, MdAH significantly decreased this might be due to the intrusion of the mandibular incisors to correct dental deep bite or deep curve of Spee, which was often found in this skeletal pattern. Some intrusion was found in the

upper incisor but MxAH was not decreased significantly.

In all vertical skeletal patterns, MxAL significantly decreased after orthodontic treatment. This may be due to the more upright inclination of anterior dentoalveolus after retraction of anterior teeth as in the studies of Ten Hoeve and Mulie(1976). Moreover, during anterior retraction, the genuine lingual root torque and bodily movement could not be achieved if root apices were moved against palatal or lingual cortex(Remmelink and van der Molen,1984).The result in this study showed the narrowest anterior dentoalveolar width in the skeletal open bite group, so it should be carefully considered when treatment plan includes large anterior retraction. The use of orthopedic forces at an early age to alter the skeletal relationship on patients with a Class II malocclusion and a severe skeletal discrepancy may be useful. In the absence of growth, combined surgical orthodontic therapy should be considered.

The dimensions of the anterior alveolus appear to set limits to orthodontic treatment, and challenging these boundaries may accelerate iatrogenic sequelae(Beckmann et al.,1998). The evaluation of maxillary and mandibular anterior dentoalveolus may be useful for predicting the outcomes of the treatment.

The limitation of this study was that the sample size of extraction case in the skeletal deep bite group was small. In addition, cephalometric radiographs are midsagittal projections; thus, the actual limit of the palate and the symphysis at the midline may be narrower than the traced image(Opdebeeck and Bell,1978; Sarikaya et al.,2002) .

Conclusion

The purpose of this study was to evaluate the anterior dentoalveolar dimensions in Thai female subjects with various vertical skeletal patterns and the changes in these dimensions after orthodontic treatment.

The conclusions of this study are:

- The width of anterior dentoalveolus was narrowest in the skeletal open bite group and widest in the skeletal deep bite group.
- The height and length of anterior dentoalveolus were longest in skeletal open bite and shortest in skeletal deep bite groups.
- After treatment, MxAW and MdAW in open bite and MdAW in normal bite groups significantly decreased.
- MxAH in open bite and normal bite groups significantly increased after treatment.
- MxAL and MdAL in all groups significantly decreased after retraction.

Acknowledgement

The researcher wishes to thank the Thai Orthodontic Foundation for providing fund for this study.

References

1. Sassouni, V. (1962) The face in five dimensions. 2nd ed. Morgantown, University Press,West Virginia.
2. Shudy, FF. (1964), 'Vertical growth versus anteroposterior growth as related to function and treatment,' Angle Orthod, 34,75-93.
3. Schendel, SA. Eisenfeld, J., Bell, WH., Epker., BN.and Mishelevich, DJ. (1976), 'The long face syndrome: Vertical maxillary excess,' Am J Orthod, 70,398-408.
4. Opdebeeck, H.and Bell, WH. (1978), 'The short face syndrome,' Am J Orthod ,; 73,499-511.
5. Dechkunakorn, S., Chaiwat, J., Sawaengkit, P. and Anuwongnukroh, N. (1994), 'Facial heights and dentoalveolar heights in Thai adults with normal occlusion,' J Dent Assoc Thai, 44,142-148.

6. Beckmann, SH., Kuitert, RB., Prahlandersen, B., Segner, D. and Tuinzing, DB. (1998), 'Alveolar and skeletal dimensions associated with overbite,' *Am J Orthod Dentofac Orthop*, 133,443-452.
7. Handelman, CS. (1996), 'The anterior alveolus: its importance in limiting orthodontic treatment and its influence on the occurrence of iatrogenic sequelae,' *Angle Orthod*, 66,95-110.
8. Wonglamsam, P., Manosudprasit, M. and Godfrey, K. (2003), 'Faciolingual width of the alveolar base,' *Aust Orthod*, 19,1-11.
9. Edwards, JG. (1976), 'A study of the anterior portion of the palate as it relates to orthodontic therapy,' *Am J Orthod*, 69,249-273.
10. Isaacson, JR., Isaacson, RJ., Speidel, TM. and Worms, FW. (1971), 'Extreme variation in vertical facial growth and associated variation in skeletal and dental relations,' *Angle Orthod*, 41,219-229.
11. Richardson, A. (1970), 'Dentoalveolar factor in anterior open-bite and deep bite,' *Dent Pract Dent Res*, 21,53-57.
12. Opdebeeck, H., Bell, WH., Eisenfeld, J. and Mishelevich, D. (1978), 'Comparative study between the SFS and LFS rotation as a possible morphogenic mechanism,' *Am J Orthod*, 74,509-521.
13. Betzenger, D. and Pancherz, H. (1999), 'The compensatory mechanism in high-angle malocclusions: A comparison of subjects in the mixed and permanent dentition,' *Angle Orthod*, 69,27-32.
14. Kraus, BS., Wise, WJ. and Frei, RH. (1959), 'Hereditiy and the craniofacial complex,' *Am J Orthod*, 45,172-217.
15. Wainwright, WM. (1973), 'Faciolingual tooth movement: its influence on the root and cortical plate,' *Am J Orthod*, 64,278-302.
16. Ten Hoeve, A. and Mulie, RM. (1976), 'The effect of antero-posterior incisor repositioning on the palatal cortex as studied with laminagraphy,' *J Clin Orthod*, 10,804-822.
17. Wehrbein, H., Privatdozent, Bauer, W., and Diedrich, P. (1996), 'Mandibular incisors, alveolar bone, and symphysis after orthodontic treatment. A retrospective study,' *Am J Orthod Dentofac Orthop*, 110,239-246.
18. Mulie, RM. and Ten Hoeve, A. (1976), 'The limitations of tooth movements within the symphysis studied with laminagraphy and standardized occlusal films,' *J Clin Orthod*, 10, 882-899.
19. Ten Hoeve, A., Mulie, RM. and Brandt, S. (1977), 'Technique modifications to achieve intrusion of the maxillary anterior segment,' *J Clin Orthod*, 11,174-198.
20. Sarikaya, S., Haydar, B., Ciger, S. and Ariyurek, M. (2002), 'Changes in alveolar bone thickness due to retraction of anterior teeth,' *Am J Orthod Dentofac Orthod*, 122,15-26.
21. Rimmelink, HJ. and van der Molen, AL. (1984), 'Effects of anteroposterior incisor repositioning on the root and cortical plate: A follow-up study,' *J Clin Orthod*, 18,42-49.