



Breast Cancer with Bone Metastases Incidentally Found in a Male Patient with Parathyroid Carcinoma Treated with Bicalutamide*

Federico Caobelli, Claudio Pizzocaro and Ugo Paolo Guerra

Department of Nuclear Medicine, Fondazione Poliambulanza, Brescia, Italy

Abstract

Parathyroid carcinoma is a rare malignant neoplasm associated with known cancer syndromes. Hyperparathyroidism, as often observed in parathyroid carcinoma, is associated with an increased risk of developing breast cancer.

A 76 year-old male patient treated with surgery and bicalutamide for parathyroid adenocarcinoma came to our observation during follow-up.

¹⁸F-FDG PET/CT showed a pathological uptake in right breast and bones, pathologically confirmed as ductal breast carcinoma.

This case supports the hypothesis of an increased risk of second malignancies in patients with parathyroid carcinoma and suggest the opportunity of starting a tamoxifen therapy in order to decrease risk of breast events.

Keywords: Parathyroid adenocarcinoma; breast cancer; bicalutamide; ¹⁸F-FDG PET/CT.

Introduction

Parathyroid carcinoma is a rare malignant neoplasm derived from the parenchymal cells of the parathyroid glands, described in a paper by Abdelgadir Adam as associated with known cancer syndromes like multiple endocrine neoplasia (MEN) types 1 and 2A. Although Patients affected by parathyroid tumor usually have a long survival, their life expectancy has been reported as reduced by Nilsson because of the increased incidence of second primary malignancies.

Hyperparathyroidism, which is often observed in parathyroid carcinoma, has been reported in papers by Norenstedt and Tanaka to be associated with an increased risk of developing breast cancer.

Also bicalutamide, often used as long time therapy in advanced prostate cancer, has

been described by Chianakwalam and Fallah as potentially inducing breast events.

We here present an unusual case of breast cancer with bone metastases, incidentally found in a Patient treated with surgery and bicalutamide for parathyroid adenocarcinoma.

* The authors disclosure of any personal or financial support or author involvement with organization(s) with financial interest in the subject matter – or any actual or potential conflict of interest.

Case Description

A 76 year-old male patient came to our observation during follow-up in order to perform a ¹⁸F-FDG PET/CT. The Patient underwent parathyroidectomy and

laterocervical lymph node dissection 3 years before after detection of adenocarcinoma of the left superior parathyroid. After surgery, radiotherapy was also performed. Familial history was positive for breast malignancies (mother).

Since histopathological examination revealed a high representation of androgen receptor, the patient received also a long-lasting adjuvant therapy with bicalutamide, 50 mg/die.

No particular symptoms were recorded by the patient, except a vague right breast pain; a mammography and breast ultrasound did not reveal any suspicion of malignancy. Neck ultrasound was also unremarkable.

Conversely, 18F-FDG PET/CT showed a focal, pathological uptake in right breast (fig. 1) and other lesions on sternum, right scapula, VII left rib, thoracic and lumbar spine (fig.2), and pelvis.

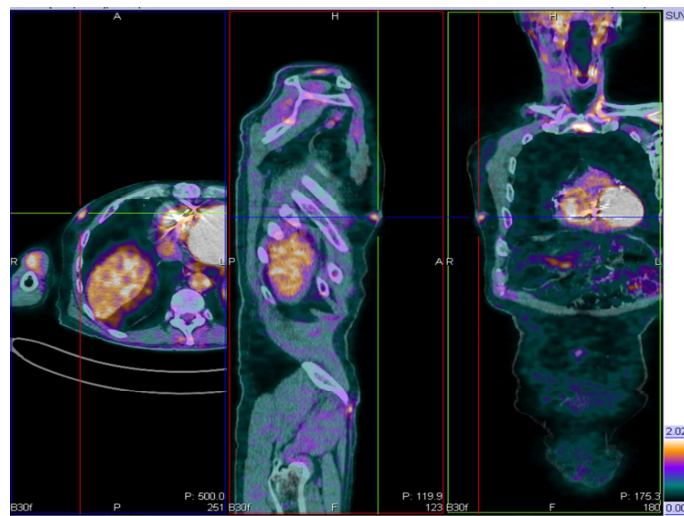


Fig. 1: transaxial, sagittal and coronal 18F-FDG PET/CT images showing a focal uptake in right breast.

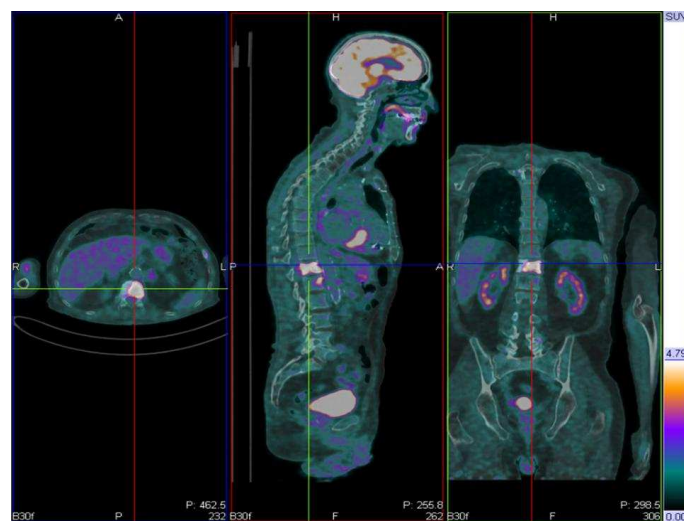


Fig. 2: transaxial, sagittal and coronal 18F-FDG PET/CT images showing an intense uptake in D12

The patient underwent further examinations: high Ca15.3 levels were found (275 UI/ml) and lesions in breast

and spine were pathologically confirmed as ductal breast carcinoma. In particular, there was an evidence of ductal structures

for both mammalian and metastatic lesions, which also had prominent nuclei, high mitotic rate (Ki67>70%) and were positive to HER2.

The patient was also investigated about genetic mutation and was found to be positive for mutation in BRCA2 gene.

Discussion

Patients affected by parathyroid tumors are at increased risk of developing second malignancies and breast as been demonstrated as having a 1.2 standardized incidence ratios in women affected by parathyroid adenoma in a study by Fallah et al.; anyway, risk of other cancers after parathyroid adenocarcinoma has been observed not to increase in the same study.

How some proteins which are overexpressed in hyperparathyroidism can increase risk of developing breast cancer has been recently investigated in many papers.

In particular, a paper by Liang et al showed that upregulation of type 1 receptor parathyroid hormone (PTH1R), associated with high levels of parathyroid hormone (PTH) are responsible of an increased proliferation and apoptosis of breast cancer cells .

Another paper by Ibaragi demonstrated that parathyroid hormone-related protein (PTHrP) might have roles in breast cancer bone metastasis independently of its roles in osteoclastic function.

Finally, also alterations of calcium serum levels have been described by Almquist as correlated with a higher risk of developing breast cancer in premenopausal and overweight women.

Taken together, all these data suggest that a pathophysiological role of endocrinological alterations observed in hyperparathyroidism, whose nature is still under active investigation, can be hypothesized in order to explain the increased risk of developing breast cancer.

The widespread bone metastases in our Patient could also be a consequence of the unbalance of many factors, caused by hyperparathyroidism.

In our case, also the fact that the patient was positive for BRCA2 gene mutation, as described for example in a review by Ghataorhe et al. and the therapy with bicalutamide could have also had a role in developing the second primary malignancy.

As described in many papers, i.e by Sieber and Chianakwalam, bicalutamide has been reported as causing an increased risk of breast events, even if a direct relationship between this therapy and breast cancer has not been demonstrated.

Anyway, there is an increasing interest in the use of prophylactic Tamoxifen therapy: as an example, a paper by Tunio suggests that Tamoxifen could be adopted in Patients treated with Bicalutamide with drug-induced gynecomastia.

To our knowledge, no cases of breast cancer in men treated with bicalutamide for a parathyroid carcinoma with high levels of androgen receptors exist in literature.

This could both support other works which highlighted the increased risk of second malignancies in patients with parathyroid carcinoma, and suggest the opportunity of starting a tamoxifen therapy in order to decrease risk of breast events.

References

Adam, M. A., Untch, B. R. & Olson, J. A. (2010). "Parathyroid Carcinoma: Current Understanding and New Insights into Gene Expression and Intraoperative Parathyroid Hormone Kinetics," *Oncologist*;15: 61–72.

Almquist, M., Bondeson, A. G., Bondeson, L., Malm, J. & Manjer, J. (2010). "Serum Levels of Vitamin D, PTH and Calcium and Breast Cancer Risk—A Prospective Nested Case–Control Study," *International Journal of Cancer*; 127: 2159–2168.

Chianakwalam, C. I., McCahy, P. & Griffiths, N. J. (2005). "A Case of Male Breast Cancer in Association with Bicalutamide-Induced Gynaecomastia," *Breast*;14:163-4.

Fallah, M., Kharazmi, E., Sundquist, J. & Hemminki, K. (2011). "Nonendocrine Cancers Associated with Benign and Malignant Parathyroid Tumors," *Journal of Clinical Endocrinology and Metabolism*; 96:E1108–E1114.

Ghataorhe, P., Kurian, A. W., Pickart, A., Trapane, P., Norton, J. A., Kingham, K. & Ford, J. M. (2007). "A Carrier of both MEN1 and BRCA2 Mutations: Case Report and Review of the Literature," *Cancer Genetics and Cytogenetics*;179(2):89-92.

Ibaragi, S., Shimo, T., Iwamoto, M. et al. (2010). "Parathyroid Hormone-Related Peptide Regulates Matrix Metalloproteinase-13 Gene Expression in Bone Metastatic Breast Cancer Cells," *Anticancer Research*;30:5029-36.

Liang, H., Zhong, Y., Huang, Y. & Chen, G. (2012). "Type 1 Receptor Parathyroid Hormone (PTH1R) Influences Breast Cancer Cell Proliferation and Apoptosis Induced by High Levels of Glucose," *Medical Oncology*; 29:439–445.

Nilsson, I. L., Wadsten, C., Brandt, L., Rastad, J. & Ekbom, A. (2004). "Mortality in Sporadic Primary Hyperparathyroidism: Nationwide Cohort Study of Multiple Parathyroid Gland Disease," *Surgery*;136:981–987.

Norenstedt, S., Granath, F., Ekbom, A. et al. (2011). "Breast Cancer Associated with Primary Hyperparathyroidism: A Nested Case Control Study," *Clinical Epidemiology*; 3:103-6.

Sieber, P. R. (2007). "Treatment of Bicalutamide-Induced Breast Events," *Expert Review of Anticancer Therapy*;7:1773-9.

Tanaka, Y. (2010). "Primary Hyperparathyroidism with Breast Carcinoma," *Breast cancer*; 17:265-8.

Tunio, M. A., Al-Asiri, M., Al-Amro, A., Bayoumi, Y. & Fareed, M. (2012). "Optimal prophylactic and Definitive Therapy for Bicalutamide-Induced Gynecomastia: Results of a Meta-Analysis," *Current Oncology*;19: e280-8.