

Effects of Early and Late Cheiloplasty on Posterior Part of Maxillary Dental Arch Development in Infants

Radovan Malina (contact author), Department of Biology and Ecology, Matej Bel University, Tajovskeho 40, 974 11 Banska Bystrica, Slovakia, e-mail: radovan.malina@umb.sk

Silvia Valentová-Strenáčiková, Clinic of Plastic, Reconstructive and Aesthetic Surgery, F. D. Roosevelt Hospital, Nam. L. Svobodu 1, 975 17 Banska Bystrica, Slovakia, e-mail: silviavs@atlas.sk

Oliver Petrík, 2nd Clinic of paediatrics anaesthesiology and intensive-care medicine, Slovak Medical University, Nam. L. Svobodu 4, 974 09 Banska Bystrica, Slovakia

Katarína Maťašová, Clinic of Neonatology, University Hospital Martin, Kollarova 2, 036 59 Martin, Slovakia

Ján Lehocký, Clinic of Plastic, Reconstructive and Aesthetic Surgery, F. D. Roosevelt Hospital, Nam. L. Svobodu 1, 975 17 Banska Bystrica, Slovakia, e-mail: jlehocky@nspbb.sk

Received date: 23 October 2013; Accepted date: 5 September 2014

No Academic Editor

Abstract

Cleft malformations belong to the most common facial congenital defects. This study compares the impact of early and late reconstruction of complete unilateral cleft lip and palate on the growth and development of the posterior part of dentoalveolar arch.

Maxillary dental casts of 35 infants were used for analyses. They were divided into 2 groups according to the timing of the lip reconstruction (group A - casts of 25 infants with early cheiloplasty and group B - casts of 10 infants with late cheiloplasty). Maxillary dental casts were taken in four periods (at the age of 14 days, 3, 6 and 12 months). The middle arch width (M-M') and intertuberosity width (T-T') of both groups were measured and compared.

This comparison showed significant differences between these two groups of infants in some periods. Early cheiloplasty has significantly affected the width of posterior part of maxillary arch. The growth of posterior part was faster in the group with early lip reconstruction.

Keywords: complete unilateral cleft lip and palate, early and late lip reconstruction, middle arch width, intertuberosity width

Introduction

Cleft malformations belong to the most common facial congenital defects. The patients are affected by cleft both aesthetically and functionally. Final result of cleft treatment depends on the appropriate choice and timing of the surgical and conservative methods. Cleft treatment is very difficult and lasts from the birth to the adulthood.

There are many different opinions of the lip reconstruction timing. Nowadays the lip repair is possible already in the first week after birth (Desay 1997, Galinier et al. 2008, Le Pendeven et al. 2009, Harris et al. 2010). Generally, the surgical reconstruction of cleft lip and palate is performed from the first hour of life to adulthood (Mazaheri et al. 1971, Millard 1976, Bromley et al. 1983). The early surgical lip reconstruction does not result in the increasing of perioperative mortality or neonatal morbidity and the result is comparable with later reconstruction (Burt, et al. 2000). Vokurková et al. (2011) suggests the 2nd day after birth as optimal time for lip reconstruction. Calteux et al. (2013) also stated very low risk of anaesthetic and surgical interventions limited to the lip before the age of 28 days and very low rate of complications.

Mazaheri et al. (1993) identified a molding effect of lip repair on the alveolar segments. They consider the molding effect responsible for the alveolar segments to come into contact with each other. However, the dimensional changes of the alveolar arch were not quantified. Honda et al. (1995) also noticed that the prominent premaxilla was set back by the pressure from the reconstructed lip in patients with complete bilateral cleft lip and palate. In a longitudinal study of children with different cleft types they supposed that cheiloplasty affected only the anterior maxillary width but not the posterior maxillary width. However, their conclusion was supported with the intercanine width only.

The aim of this study was to compare and quantitatively analyze the development of the posterior part of the maxillary dental arch after the early and late reconstruction of the complete unilateral cleft lip and palate.

Materials and methods

The presented longitudinal study was realised in the years 2008 - 2012 at the Clinic of Plastic, Reconstructive and Aesthetic Surgery in Banská Bystrica. The sample consisted of 35 infants' maxillary dental casts with complete unilateral cleft lip and palate. All infants were born after the 37th week of pregnancy. Maxillary dental casts were taken of these 35 infants in four periods – at the age of 14 days, 3, 6 and 12 months. All casts were divided into 2 groups according to the timing of the lip reconstruction.

Group A consisted of casts of 25 infants with early lip reconstruction (reconstruction was performed in the first 14 days of their life). This group consisted of 13 boys and 12 girls. Left-sided cleft was present in 16 infants and the right-sided in 9 infants. Only the children in excellent health state without an associated inborn defect were included in this group.

Group B consisted of casts of 10 infants with later lip reconstruction (reconstruction was performed at the age of 3 months). The group consisted of 5 boys and 5 girls. Left-sided cleft occurred in 4 infants and the right-sided in 6 infants. Early lip reconstruction could not be performed in this group due acute respiratory infections.

The complete cleft was surgically solved in two stages. The first stage was the reconstruction of lip and nose using the Millard's technique with the reconstruction of the nasal wing. The second stage included the palate reconstruction using four flap palatoplasty technique of Wardil-Kilner. All reconstructions were performed by the same surgeon.

The anthropometric points (Fig. 1) were identified on each dental cast. To analyze the development of posterior part of maxillary arch we used standard anthropometric parameters according to Mazaheri et al. (1971). We measured the following linear distances:

M-M' - middle arch width;

T-T' - intertuberosity width.

Linear measurements were realised with a digital slide caliper with an accuracy of 0.1 mm. To minimize errors each dimension was measured by three examiners and the average value was determined. The sets of measurements of one examiner were not available to the others.

The PASW Statistics 18 (SPSS Inc., Chicago, IL, USA) was used for statistical analyses. First, the normality of data was verified by Shapiro-Wilk W test. The data with the normal distribution were analysed by ANOVA, remaining data were analysed by the nonparametric Wilcoxon test. The significance level was established at $\alpha=0.05$.

Results

In the group A, the middle arch width (M-M') continuously increased during observed period. The average distance of M-M' was 33.47 mm before the lip reconstruction (Table 1). The steepest incline was observed in the last three months (Fig. 2). At the age of 1 year, the M-M' distance was 43.22 mm in this group.

In the group B, the middle arch width (M-M') increased equally during whole observed period (Fig. 2). The average distance of M-M' was 34.92 mm before the lip reconstruction and 40.95 mm at the end of the observed period (Table 1).

There was no significant difference in the middle arch width (M-M') between group A and B in the age of 14 days. Significant differences has appeared at the age of 3 months and lasted to the end of observed period (Table 1).

The intertuberosity width (T-T') was almost identical in both groups before lip reconstruction. In group A, the intertuberosity width (T-T') had slightly increased during first 3 months of life and then the increasing was steeper. In group B, the intertuberosity width (T-T') increased equally during whole observed period (Fig. 2).

There were significant differences in the intertuberosity width at the age of 3 months and 1 year respectively (Table 1).

Discussion

This longitudinal study of a group of 35 infants with the complete unilateral cleft lip and palate compared the development of the posterior segment of the dentoalveolar arch of infants with the early and late correction of the cleft.

There were significant differences in the middle arch width at the age of 3, 6 and 12 months respectively. The middle arch width was continuously increasing during whole observed period. Continual increasing of middle arch width stated also Huang et al. (2002) in infants with late cheiloplasty. In our study, this increasing was slightly faster in group A (early lip reconstruction) at the end of observed period. Difference between both groups was notable at the age of 1 year especially.

The intertuberosity width (T-T') was continuously increasing also. This increasing was slower in group A than in group B for first three months of observed period. This is due to early cheiloplasty in group A. The differences gradually disappear and there are no significant differences at the age of 6 months. The intertuberosity width of the group A is significantly greater than in the B group at the end of observed period. Kramer et al. (1996) focused on palatal growth in relation to timing of surgery. When the operation was performed later, the intertuberosity width was temporarily larger in comparison to early closure. However, they measured it at the age of 9 months and this difference was not significant.

Continual increasing of T-T' stated also Huang et al. (2002) and Reiser et al. (2013) in infants with late cheiloplasty. Kramer et al. (1994) also stated continual increasing of T-T' in infants with unilateral cleft, bilateral cleft and in infants without cleft.

The early lip reconstruction had no detrimental effect on posterior part of dental arch. Furthermore it has important positive impact on infants and their parents. As found out Borsky et al. (2012), this early solution not only facilitated baby feeding, but had important positive psycho-social impact on the whole family. Feeding difficulties reported in infants with cleft lip and/or palate were reduced after neonatal cleft lip repair (McHeik and Levard 2010) and McHeik and Levard (2006) noted that

most mothers preferred their infant to receive neonatal repair and great satisfaction after neonatal cleft lip repair.

Conclusion

This study compares differences in development of posterior part of maxillary dental arch after early and late cheiloplasty in infants with unilateral complete cleft lip and palate. It demonstrates that there are significant differences between these two groups of infants in some periods.

The middle arch width was expanding faster in the group with early lip reconstruction. The difference between both examined groups was highly significant at the end of observed period.

Also, the intertuberosity width was expanding faster in the group with early cheiloplasty. This faster expansion started at the age of 3 months and lasted to the end of observed period. During first 6 months of life, the intertuberosity width was broader in the group with late lip reconstruction. After this period the width was broader in the group with early lip closure.

Early cheiloplasty has significantly affected the width of posterior part of maxillary arch. The growth of posterior part was faster in the group with early lip reconstruction.

Our team will continuously observe the development of maxillary dental arch of these babies till adulthood to appreciate the impact of early lip reconstruction.

References

Borsky J., Velemínska, J., Jurovčík, M., Kozak, J., Hechtová, D., Tvrdek, M., Cerný, M., Kabelka, Z., Fajstavr, J., Janota, J., Zach, J., Peterková, R. and Peterka, M. (2012) "Successful early neonatal repair of cleft lip within first 8 days of life," *Int J Pediatr Otorhinolaryngol* 76 (11):1616-26.

Bromley, G. S., Rothaus, K. O. and Goulian, D. (1983) "Cleft lip: morbidity and mortality in early repair," *Ann Plast Surg*. 10 (3) 214-217.

Burt, J. D. and Byrd, H. S. (2000) "Cleft Lip: Unilateral Primary Deformities," *Plastic & Reconstructive Surgery* 105 (3) 1043-1055.

Calteux, N., Schmid, N., Hellers, J., Kumpan, S., and Schmitz, B. (2013). "Neonatal cleft lip repair: Perioperative safety and surgical outcomes," *Ann Chir Plast Esthet*. 58 (6):638-43.

Desai, S. (1997) *Neonatal Surgery of the Cleft Lip and Palate*. World Scientific Publishing, Singapore

Galinier, P., Salazard, B., Deberail, A., Vitkovitch, F., Caovan, C., Chausseray, G., Acar, P., Sami, K., Guitard, J. and Smail, N. (2008). "Neonatal repair of cleft lip: a decision-making protocol," *J Pediatr Surg*. 43 (4):662-7.

Harris, P.A., Oliver, N.K., Slater, P., Murdoch, L., and Moss A.L. (2010). "Safety of neonatal cleft lip repair," *J Plast Surg Hand Surg*. 44 (4-5):231-6.

Honda, Y., Suzuki, A., Ohishi, M. and Tashiro, H. (1995) "Longitudinal study on the changes of maxillary arch dimensions in Japanese children with cleft lip and/or palate: infancy to 4 years of age," *Cleft Palate Craniofac J*. 32 (2) 149-155.

Huang, Ch. S., Wang, W. I., Chen, Y. R., Chen, P. K. T. and Noordhoff, M. S. (2002) „Effects of Cheiloplasty on Maxillary Dental Arch Development in Infants with Unilateral Complete Cleft Lip and Palate," *Cleft Palate Craniofac J*. 39(5) 513-516.

Kramer, G. J. C., Hoeksma, J. B. and Prah-Andersen, B. (1994) "Palatal changes after lip surgery in different types of cleft lip and palate," *The Cleft Palate-Craniofacial Journal* 31 (5) 376-384.

Kramer, G. J. C., Hoeksma, J. B. and Prah-Andersen, B. (1996) "Early Palatal Changes after Initial Palatal Surgery in Children with Cleft Lip and Palate," *The Cleft Palate-Craniofacial Journal* 33 (2) 104-111.

Mazaheri, M., Harding, R. L., Cooper, J. A., Meier, J. A. and Jones, T. S. (1971) "Changes in arch form and dimensions on cleft patients," *Am. J. Orthod.*, 60 (1) 19-32.

Mazaheri, M., Athanasiou, A. E., Long, R. E. and Kolokitha, O. G. (1993) "Evaluation of maxillary dental arch form in unilateral clefts of lip, alveolus, and palate from one month to four years," *Cleft Palate J.* 30 (1) 90-93.

McHeik, J.N. and Levard, G. (2010) "Growth in infants in the first two years of life after neonatal repair for unilateral cleft lip and palate," *Int J Pediatr Otorhinolaryngol.* 74 (5):465-8.

McHeik, J.N. and Levard, G. (2006) "Neonatal cleft lip repair: psychological impact on mothers," *Arch Pediatr.* 13 (4):346-51.

Millard, D. R. (1976) *Cleft Craft: The Evaluation of Its Surgery*, vol 1. Little, Brown, Boston

Le Pendeven, R., Martinot-Duquenois, V. and Pellerin P. (2010) "Long-term morphologic results of a 32 successive patients series presenting unilateral complete cleft lip and palate with surgery at early age," *Ann Chir Plast Esthet.* 54(1):7-15.

Reiser, E., Skoog, V. and Andlin-Sobocki, A. (2013) "Early dimensional changes in maxillary cleft size and arch dimensions of children with cleft lip and palate and cleft palate," *The Cleft Palate-Craniofacial Journal* 50 (4) 481-490.

Vokurková, J. J., Elstnerová, L. L., Lukášová, O. O., and Huřová, I. I. (2011) "Vývoj neonatální péče a zhodnocení zkušeností prvních pěti let operací rozštěpu rtu v neonatálním období," (Czech). *Czecho-Slovak Pediatrics / Cesko-Slovenska Pediatrie*, 66(6) 356-362.

Table 1: The measurements of maxillary dental arch during observed period in infants with the early (A) and late (B) cheiloplasty.

	In the first 14 days		3 months		6 months		1 year	
	A	B	A	B	A	B	A	B
M-M'	33.47±2.99	34.92±0.69	36.14±0.39 **	37.07±0.57 **	38.62±0.70 *	39.23±0.68 *	43.22±0.54 **	40.95±0.99 **
T-T'	31.24±1.22	31.20±0.99	32.09±0.56 **	33.23±0.54 **	34.81±0.89	35.19±0.70	37.14±0.61 *	36.72±1.10 *

*The difference between the early (A) and late (B) cheiloplasty is significant ($p < 0.05$)
 ** The difference between the early (A) and late (B) cheiloplasty is highly significant ($p < 0.001$)




Fig. 1: Identification of individual landmarks used in measurements.

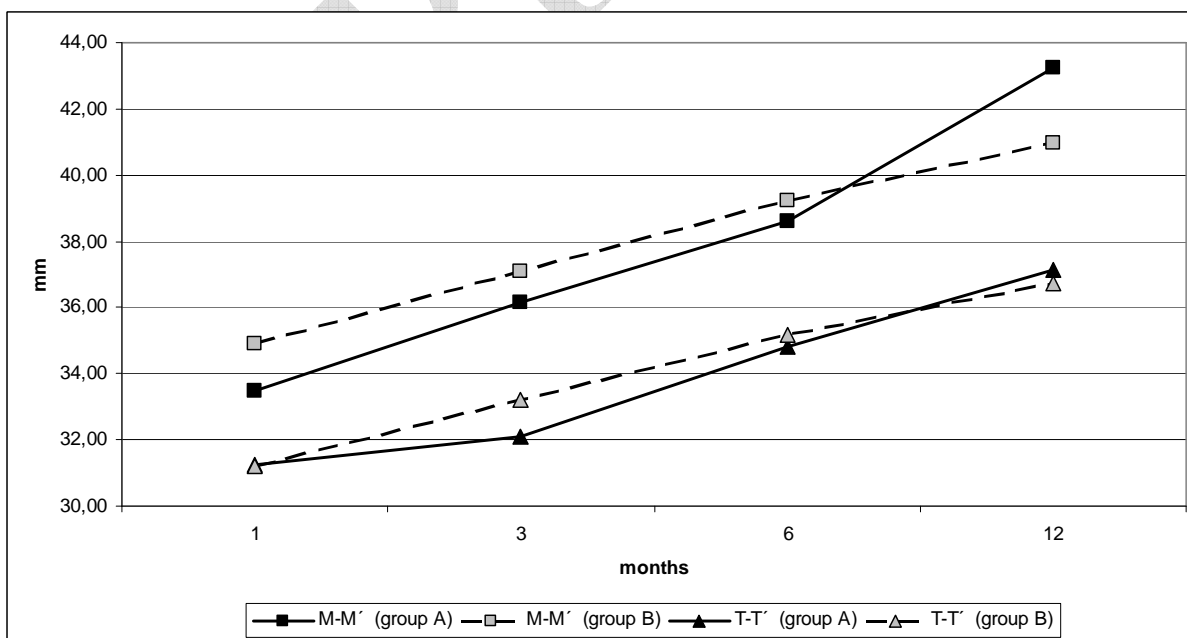


Fig. 2: Changes in linear lengths M-M' and T-T' of maxillary dental arch during the observed period in infants with the early (group A) and late (group B) lip repair.