



Research Article

The Subcutis Ultrasound Map of Type 1 Diabetic Children Improves the Diagnosis of Local Dystrophies and Insulin Injection Technique

Rodica Perciun¹ and Mihaela Mihu²

¹Institute of Diabetes, Nutrition and Metabolic Diseases, Bucharest, Romania

²Children's Emergency Hospital "Marie Sklodowska Curie", Bucharest, Romania

Correspondence should be addressed to: Rodica Perciun; rodicaperciun@gmail.com

Received Date: 28 October 2013; Accepted Date: 2 January 2014; Published Date: 21 March 2014

Academic Editor: Raffaella Mormile

Copyright © 2014 Rodica Perciun and Mihaela Mihu. Distributed under Creative Commons CC-BY 3.0

Abstract

The motivation of this article is to diagnose local insulin related dystrophies and their dynamic with an ultrasound (US) subcutis (SC) map, by comparison with clinical data. To improve insulin injection technique by identifying the real cutis/subcutis thickness (CST).

We have enrolled 53 type 1 diabetic children (33 boys and 20 girls, aged between 2 and 15 years), with diabetes duration between 1 and 13 years. The clinical examination puts into evidence three types of local dystrophies: hypertrophy, nodular lumps and atrophy. The US technique has confirmed clinical findings and moreover has diagnosed their location, size, depth and echostructure. While mapping dystrophies we simultaneously have taken into consideration the CST of the nearest non-injured areas in order to be compared. The screening was also made again after a 6 months period.

The US interrogation revealed a larger diversity of dystrophic phenomenon than the clinic one: SC diffuse hypertrophy, dominant nodular aspects, atrophies, associated muscular dystrophy or multiple layer dystrophies. After a 6 months period of not injecting, the clinical examination diagnosed the remission of some hypertrophies and nodular aspects. Also as a confirmation, the US technique identified more residual images and certified which types of echostructures had recovered or not.

Local insulin dystrophy would be diagnosed, typified and mapped effectively by US unlike clinical severity. Reinjecting would be safer done after the US re-examination has certified the level of recovery. Being a comparative term as well as a condition for improving the injection technique the mapping of normal CST might be also part of a continuous specific education of insulin treated patients.

Keywords: Type 1 diabetes, insulin dystrophy, ultrasound subcutis map, education.

Introduction

The normal cutis and SC layers are essential for insulin injecting efficiency and also for its action predictability. Local dystrophic lesions are frequently noticed irrespective of the insulin type or of the subjects' age. The dystrophies can be clinically diagnosed as either hypertrophic, nodular or atrophic. The SC remodelling is a local consequence of some factors such: very frequently injected areas, duration of treatment, inappropriate injecting technique, needle's quality, physico-chemical properties of insulins or individual response as suggested by Lo Presti (2012), Hofman (2007, 2010), Bierkebaek (1998), Wallymahmed (2004) and Hildebrandt (1991). Lipodystrophies were noticed when the administration route was either a portable pump or boluses as Rademecker (2007) had found. Thus, the early detection of local dystrophies and the evaluation of the anatomodynamic features during the long lasting insulin treatment are important especially when very young people are involved.

The clinical inspection and palpation may evaluate some superficial abnormalities. However, it is not sufficient to appreciate the real depth and the number of the involved anatomic layers. Therefore, a highly accurate, noninvasive and fully safe US imaging technique as Bianchi and Martinolli (2007) demonstrated, needs to be taken into account. We described (2010, 2012) some different US aspects of insulin related dystrophic areas: diffuse hypertrophy, nodular (with various degrees of diffuse SC dystrophy), muscular and multilayer lesions (cutis/SC/muscularis) or atrophic. Except the clinical changes there is no description of different US dynamic stages in a certain period of time. The recommendations of the current guidelines like EADV Guideline (2008), AADE (2011) and ISPAD Clinical Practice Consensus (2009) for handling insulin injections couldn't hinder the local insulin side effects. We think that one of the reasons would be the absence of an accurate evidence of individual anatomic condition of the injected areas.

The caregivers face themselves with a multitude of specific problems, but usually they underestimate the real amplitude and consequences of SC dystrophies.

Aim of the Study

In the current study we intended to emphasize the discrepancy between the clinical findings'pooreness versus US multifaceted imaging while diagnosing local insulin dystrophies. Their mapping has also offered some objective and specific details about CST of the nearby normal tissues so that we further aimed to use it for improving insulin injecting technique.

Methods

Study Population

We decided to collect data from 53 patients, from the large sample insulin dystrophic population, who were the only ones that could be reexamined after 6 months. The group was made of 33 boys and 20 girls, aged 2-15 years, with diabetes duration between 1-13 years. According to their BMI, 15 children were underweight, 32 were normalweight and 6 were overweight. All participants had clinically been diagnosed as having one or more SC dystrophies. That is a total of 149 abnormal areas. Clinic relevance was based upon physical examination. By adding the noninvasive imaging US technique more anatomic details could be unveiled.

Technical Data

The study has been approved by the local ethical committee. The written informed consent of the patients' parents has also been obtained.

The clinical examination was made and the dystrophic areas were photo- recorded (arms, abdominal wall, thighs and buttocks).

The form entitled "Map of the insulin injected areas" includes the patient's general information, anthropometry and some medical history data. We marked the dystrophic projection areas within the

conventional areas to be injected along with clinical description (hypertrophy, nodular, atrophy). Every injured area has been US scanned and identified as diffuse hypertrophy, nodular, atrophy, muscular or multilayer lesion (different simultaneous degrees of cutis/SC/muscularis injuries). The US scanning also helped us to have an accurate deliniation between dystrophy and normal areas. We recorded data about the current injecting technique, needle

length, their reuse and insulin needs. Collectively, these data enabled us to recommend a proper technique and device for every specific anatomic area (different areas having different CST). According to the protocol, every injured area was clinically and US scanned after 6 months. We used a B mode US technique with color/pulsate wave facilities. It was an Aloka US diagnostic equipment with 7.5-10 MHz linear transducer.

Map of the Insulin Injected Areas

D/M/Y.....Physician.....Phone.....

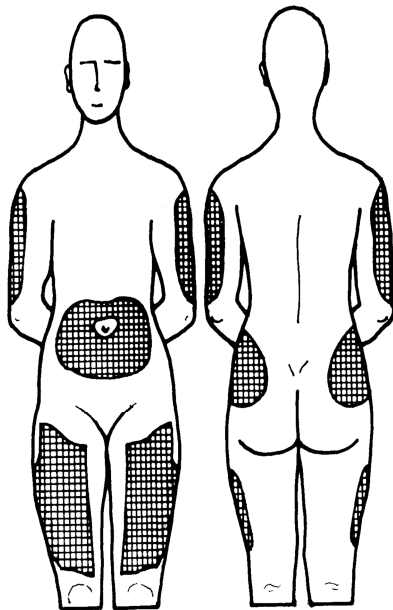
Name.....Age.....

Duration of diabetes.....Insulin schedule.....boluses/pump

Height.....Weight.....BMI.....

Normal areas to be injected	Skinfold (±FATTRACK) mm	US cutis CSTmm	Needles to be used	Injection technique to be used: skinfold and angle no skinfold
Arm:anterosup. aspect				
Arm: lateral aspect				
Upper abdominal wall				
Lower abdominal wall				
Thigh: anterior aspect				
Thigh: lateral aspect				
Buttock				

Dystrophic Areas



<u>Clinic</u>	<u>US</u>	<u>Needles</u>
Hypertrophy	Hypertrophy	Reuse
Atrophy	Nodular	Length
Nodular	Atrophy	
	Muscular	
	Multilayer	

Current inj technique arm abd.wall thigh

- appropriate
- inappropriate

<u>Insulin needs</u>	<u>US/ 6 months</u>
initially	recovery
after rotation	non recovery

Figure 1: The Form Entitled “Map of the Insulin Injected Areas “Contains General and Specific Medical Information and a Body Map with Clinically/US Injured Areas and the Recommendations (Normal Areas to be Injected, Technique and Needles). The Evolution of Dystrophies is Also Recorded after 6 Months.

Results

Table 1. Dystrophies: Clinical Signs versus Ultrasound Types and Dynamics

Clinical			Ultrasonography		
DOMINANT SIGN	Initial	After 6 m-ths	US type	Initial	After 6 m-ths
a. HYPERTROPHIES	118	62	1.diffuse	60	16
			2.with nodular-shaped dystrophy (not palpable)	11	2
			3.with muscular dystrophy	23	23
			4.multilayer	24	24
binocular LUMPS (palpable)	19	2	1.nodular dystrophy	2	2
			2.with hypertrophy	5	2
			3.with muscular dystrophy	12	12
c. ATROPHIES	12	12	1.SC atrophy	2	2
			2.with muscular dystrophy	10	10

Table 2. Dystrophic Remission: Clinical versus US

	Clinical remissions	US remissions
HYPERTROPHY	56	53
NODULAR LUMPS	17	3
ATROPHIES	0	0

The injured areas were clinically classified by using the dominant sign. However, every clinical type surprisingly displayed us in isolation or in association multiple US echostructures that are overlapped (Table 1.) The muscular dystrophies cannot clinically be appreciated in isolation. We have 45 (30.20%) injured muscular echostructures (a.3., b.3., c.2.) which are hidden by SC clinically obvious dystrophies. We could see muscular injuries only by US. The multilayer dystrophies, counting 24 (16.10%) echostructures, were clinically perceptible as a result of SC hypertrophy, too (a.4.). The lipoatrophy was clinically diagnosed as an excavation of the SC injected areas being frequently associated with focal muscular dystrophy (c.).

Despite avoiding insulin injections for 6 months, the injured areas displayed 62 (out of 118) clinical residual hypertrophies vs. 65 echostructures (Fig.3). The remaining palpable nodular lumps were 2 (out of 19) vs 16 echostructures (Fig.4). The total

number of nodular dystrophies was 30 (20.13%) (out of 149). Either palpable (b.) or not (a.2.) they were US diagnosed. We mention that the nodular forms which are embedded within hypertrophic substantial reaction (a.2., b.2.) are more sensitive to remission. There was no US remission at all for atrophies (Fig.5), muscular layer itself (Fig.6) or multilayer dystrophies (Fig.7). Looking at these findings, we consider that, US was the only objective criterion for evaluating the dynamic aspects of dystrophies. (Table 2). The normalweight children but mainly the underweight ones, expressed the majority of muscular dystrophies (35 of 45). We have US diagnosed all of the 6 pump users with 20 (out of 24) multilayer dystrophies (a.4) irrespective of their BMI, age or insulin pump treatment duration.

We found no significant relationship between age, diabetes duration, BMI, HbA1c and dystrophies' characteristics and dynamic.

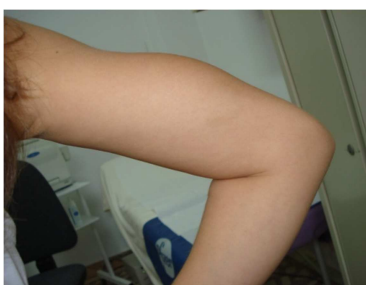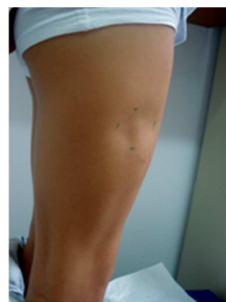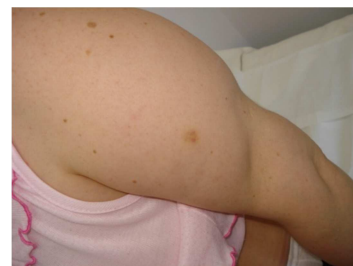**Figure 2a****Figure 2b****Figure 2c**

Figure 2: Some Images Depicted at Physical Inspection a) Dystrophic Hypertrophy, b) Dystrophic Atrophy and c) a Hypertrophic Nearby Atrophic Areas.

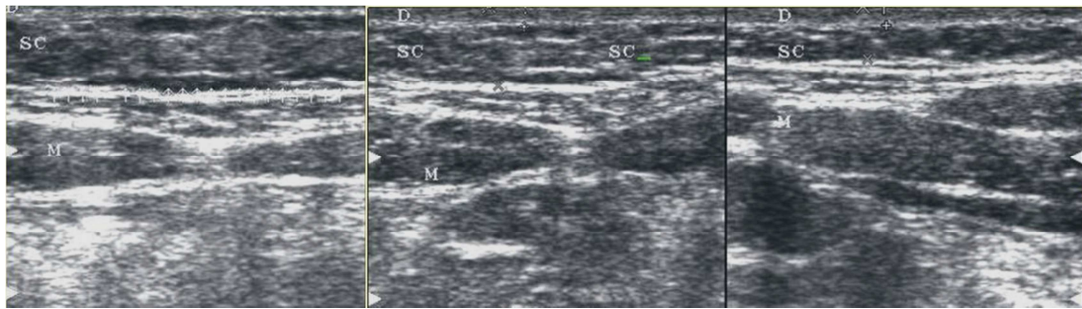


Figure 3: Abdominal Wall. Diffuse SC Hypertrophic Dystrophy (Left-0.84cm) vs Partial Remission at 6 Months (Middle-0.55cm) by Comparison with a Normal Nearby Area (Right-0,35cm).

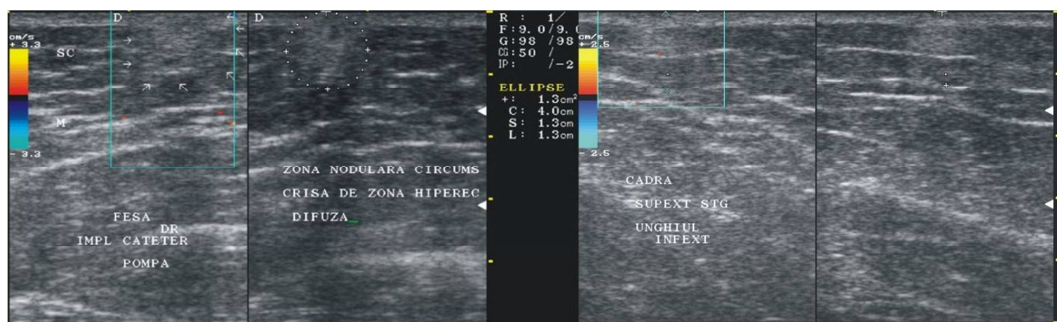


Figure 4: Buttock. Nodular Dystrophic Areas with Initially Higher Echogenicity and No Cutis/SC Delineation (Left) vs Lower Echogenicity and Inacurate Delineated Nodular Borders after 6 Months (Right).

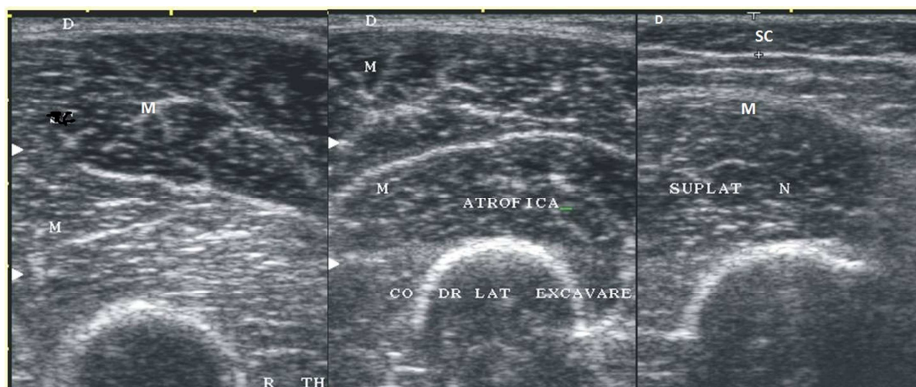

Figure 5 : Thigh. An Area without SC Tissue. A Total SC Atrophy Initially (Left) and after 6 Months (Middle) vs a Nearby Normal Area (Right).

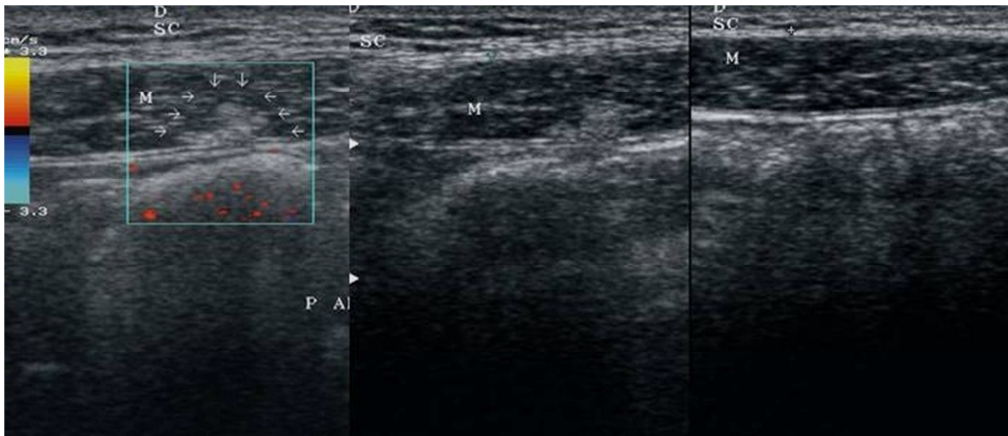


Figure 6 a: An Underweight Child with Almost Fat Free SC Layer within Abdominal Wall. The Same Muscularis Injured Area, Initially (Left), and after 6 Months (Middle) vs the Nearest Normal Tissue (Right).

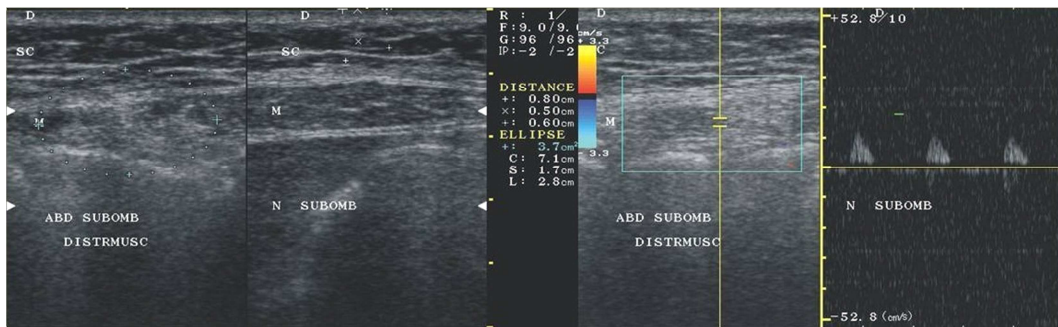


Figure 6 b: A Normalweight Child with Well Represented SC Layer Fat within Lower Abdominal Wall. An Initial Dystrophic Muscularis Area (Left) vs Normal (Right on the Split Screen Image). After 6 Months, the Same Dystrophic Area with Some Doppler Arterial Flow (Right).

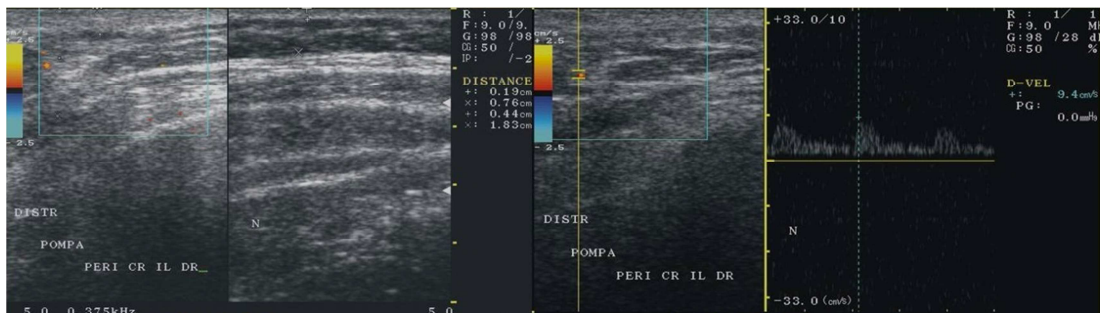

Figure 7 : A Lower-Lateral Abdominal Area Repeatedly Infused by Pump. A Complex Multilayer Dystrophy with No Clear Delimitation between Cutis, SC and Muscularis, Initially (Left) vs Normal Nearby Aspect (Right on the Split Screen Image). After 6 Months there is No Remission; Color/pw Arterial Doppler Signal Can Be Seen (Right).

Discussion

Physical exam is able to diagnose SC dystrophies usually as hypertrophies, nodular lumps or atrophies. In everyday practice no other investigation is usually made and the only advice one could give is to skip these areas from insulin injections for several months or better until the previous normal aspect is clinically regained.

The dynamic anthropometry of children between childhood and adolescence is impressive. The small children have tiny conventional areas to be injected and a millimetric CST. Whatever the route of insulin injection (boluses or pump) is, there are no many options in terms of rotation or a safety place for injection. The children, mainly under-or normalweight actually get a 1-2mm SC thickness in some areas (upper abdominal wall, upper/lateral aspects of arms and thighs) (Fig.6 a). Neither a pinched skinfold nor an angled insulin injection of the shorter needles (4-5mm) are sufficiently safe to entirely avoid the muscularis, as Lo Presti' US study (2005) and Hofman (2010) suggested. As they physically grow the children can get larger and thickened fatty areas, needing accordingly different injecting techniques and needle length. It is well known that highly vascularized muscularis gives a higher and more rapid insulin absorption when injecting as Hofman (2010), Bierkebaek (2008) and Polak (1996) found. As a consequence, some hypoglycemic reactions cannot be avoided. In our study the young patients with muscular and multiple layer dystrophy have declared less hypoglycemic reactions after rotating the place of injectate. The pump users noticed lower insulin needs when rotating. However, no significant relationship was found between HbA1c, age, duration of insulin treatment, multiple injections therapy or BMI and types of dystrophies for a period of 6 months.. We must emphasize that 10 out of 53 children, have developed SC dystrophic hypertrophy within first 2-5 months after starting the treatment. This shows how important is an early effective prevention. For the rest of the children the diagnosis was made when

they had already been enrolled in our study. Some children and parents had previously noticed more pain and needle damage when injecting probably through nodules or muscular layer. It was almost a constant fact that the skinfold had incorrectly pinched up including the muscle. Moreover, releasing the skinfold too soon muscularis could also be injured. This wrong technique seems to be a plausible explanation for the multitude of muscular injuries. We noticed frequently, in our study group, that the reuse of needles was higher than 5 times. A lower insulin dosage usually means a longer usage of the same needle. This is a consequence of not getting free of charge, more than one needle per cartridge. Whenever the shorter needles are not available or parents are not trained to make a proper insulin device's choice, we face another potential dystrophic risk factor.

There are some findings which suggest why the patients should no longer inject the dystrophies. A poorer absorption could affect the predictability of the injectate as Johansson (2005), AADE (2011) and other researchers agree. Even more, the texture of lipodystrophy can alter in different manners the insulin absorption as Wallymahmed has found (2004). It is a matter of decreasing the surface of the available areas, besides producing an unaesthetic anatomic shape. Fourteen children (26.41%) from our study regained their normal anatomic shape after 6 months We have already depicted back in 2012, an exceptional thickened cutis, for the adults, of 6.8 mm, as a component of the cutis/SC dystrophic tandem. Either using insulin boluses or pump, the shortest needles, might not reach the SC layer, insulin delivering being within cutis. This could be a good reason to measure, separately and together, the cutis and SC layers. Although in Pettis and Gupta's studies (2011) is stipulated a more rapid insulin pharmacokinetics when intradermal insulin has been infused there is yet no general consensus on this fact. Even more, the intradermal injectate can lead to an immune reaction, insulin leakage, and also can be painful as Hofman (2010) suggested.

Clinically, the hypertrophies are far the most common SC dystrophies. Palpable or not, the nodular lumps are also suggesting a SC remodelling process. We have obtained an imagistic confirmation of clinical lesions either hypertrophic, nodulars or atrophic. But we have gotten many other US echostructures within each clinical dystrophic type thus giving a better anatomic perception of local insulin dystrophies (Table 1). We have confirmed that hidden and more versatile echostructures are involved as Wallymahmed (2004) and our study (2010) suggested.

The US described, clinically innaparent nodules, muscular reactions and complex multilayer dystrophies which became obvious only when embedded within dystrophic SC layer. Our US study has revealed that there was no remission of muscular and multilayer dystrophies after 6 months, despite a certain regression of the SC hypertrophy. Taking into consideration all these facts, it is unlikely to make a valuable clinical estimation about the proper reinjecting time. This is another reason for US screening map.

In order to be more accurate every US dystrophy was compared with the nearest normal area of the same anatomic segment. Thus the choice of the injecting technique or the needle length is strongly influenced by the non-injured anatomic layers. It is an important step for improving the injecting technique. It could be difficult sometimes to diagnose the delineation between normal cutis/ SC layers but, as Gibney's US study (2010) of the injected sites suggested, US scanning offers the highest accurate estimation.

The skinfold is made by the apposition of double cutis and double SC layers that are compressed, pinched and lifted. It is used as an injection technique and also a surrogate for CST. Dividing by 2 the skinfold thickness measurement (done using a fat-track or the fingers), we obtain the CST itself (unlifted skinfold) as Selkow (2011) and Hildebrandt (1993) estimated. By clinically estimating as above, the CST, for a given anatomic area, we can choose

the needle length and the injection technique. Some difficulties were found when performing the above technique on the buttocks and lateral aspects of the thighs for the overweight children in the study group. However, US interrogation in terms of CST measurements of normal conventional areas has dramatically improved the insulin injecting technique and the device's choice. Our study population has shown no new dystrophies after six months. It is known that SC atrophy is the consequence of an immune complex-mediated inflammatory process as Radermecker (2007) suggested. After reconsidering the type of insulin and injecting areas no other SC atrophies appeared but no remission was seen for the existing ones. Once the dystrophies have appeared we think that a periodical US examination, will enable the patients and the caregivers to reconsider the injected areas and the injection technique. Although, the routine clinical examination of SC injured areas can not be replaced, an US expertise is needed and is useful. Conducting a study on a larger young affected population for a longer period of time would sustain the need for US besides the clinical examination.

Conclusion

Once appeared, the dystrophic areas should be mapped and US typified despite their clinical appearance. The decision of reinjecting should be done right after the US interrogation. In order to improve the insulin injection technique a SC ultrasound reference map should be used because it shows the real CST. A continuous education of the young diabetic patients should consider both US and clinical procedures.

References

- AADE (2011). 'Strategies for Insulin Injection Therapy in Diabetes and Self-Management,' *American Association of Diabetes Educators, BD Medical Diabetes Care*.
- Bangstad, H. J., Danne, T., Deeb, L., Chobot, P. J., Urakami, T. & Hanas, R. ISBAD Clinical Practice Consensus Guidelines

- Compendium. (2009). "Insulin Treatment in Children and Adolescents with Diabetes," *Pediatric Diabetes*, 10 (Suppl.12) 82-99.
- Bianchi, S. & Martinolli, C. (2007). *Ultrasound of the Musculoskeletal System*, Springer, Berlin, Germany.
- Birkebaek, N. H., Johansen, A. & Solvig, J. (1998). "Cutis/Subcutis Thickness at Insulin Injection Sites and Localization of Simulated Insulin Boluses in Children with Type 1 Diabetes Mellitus: Need for Individualization of Injection Technique?," *Diabetic Medicine*, 15 (11) 965-971.
- Birkebaek, N. H., Solvig, I., Hansen, B., Jorgensen, C., Smedegaard, J. & Christiansen, J. S. (2008). "A 4-mm Needle Reduces the Risk of Intramuscular Injections without Increasing Backflow to Skin Surface in Lean Diabetic Children and Adults," *Diabetes Care*, 31 (9) e65.doi:10.2337/dco8-o977
- EADV Guideline (2008). 'The Administration of Insulin with Insulin Pen,' EADV (Association of diabetes nursing specialists), Utrecht.
- Gibney, M. A., Arce, C. H., Byron, K. J. & Hirsch, L. J. (2010). "Skin and Subcutaneous Adipose Layer Thickness in Adults with Diabetes at Sites Used for Insulin Injections: Implications for Needle Length Recommendations," *Current Medical Research & Opinion*, 26 (6) 1519-1530.
- Gupta, J., Felner, E. & Prausnitz, R. (2011). "Rapid Pharmacokinetics of Intradermal Insulin Administered Using Microneedles in Type 1 Diabetes Subjects," *Diabetes Technology & Therapeutics*, 13(4) 451-456.
- Hildebrandt, P. (1991). 'Subcutaneous Absorption of Insulin-Dependent Diabetic Patients. Influence of Species, Physico-Chemical Properties of Insulin and Physiological Factors,' *Danish Medical Bulletin*, 38 (4) 337-384.
- Hildebrandt, P. & Vaag, A. A. (1993). "Local Skin-Fold Thickness as a Clinical Predictor of Depot Size during Basal Rate Infusion of Insulin," *Diabetes Care*, 16 (1) 1-3.
- Hofman, P. L., Derraik, J. G. B., Pinto, T. E., Tregurtha, S., Faherty, A., Peart, J. M., Drury, P. L., Robinson, E., Tehranchi, R., Donsmark, M. & Cutfield, W. S. (2010). "Defining the Ideal Injection Techniques when Using 5-mm Needles in Children and Adults," *Diabetes Care*, 33 (9) 1940-1944.
- Hofman, P. L., Lawton, S. A., Peart, J. M., Holt, J. A., Jefferies, C. A., Robinson, E. & Cutfield, W. S. (2007). "An Angled Insertion Technique Using 6-mm Needles Markedly Reduces the Risk of Intramuscular Injections in Children and Adolescents," *Diabetic Medicine*, 24 (12) 1400-1405.
- Johansson, U. B., Amsberg, S., Hannerz, H. J., Wredling, R., Adamson, U., Arnqvist, H. J. & Lins, P-E. (2005). "Impaired Absorption of Insulin Aspart from Lipohypertrophic Injection Sites," *Diabetes Care*, 28 (8) 2025-2027.
- Lo Presti, D., Ingegnosi, C. & Strauss, K. (2012). "Skin and Subcutaneous Thickness at Injecting Sites in Children with Diabetes: Ultrasound Findings and Recommendations for Giving Injection," *Pediatric Diabetes* (Impact Factor.2.08). 05/2012; DOI:10.1111/j.1399-5448.2012.00865.xSource: PubMed.
- Perciu, R. (2010). "Ultrasonographic Aspect of Subcutaneous Tissue Dystrophies as a Result of Insulin Injections," *Medical Ultrasonography*, 12 (2) 104-109.
- Perciu, R., Telcian, A. & Olariu, L. (2012). "Ultrasound Assessment of Cutaneous/Subcutaneous Dystrophies in Insulin-Treated Patients. A Report on Two Cases," *Medical Ultrasonography*, 14 (1) 60-63.
- Pettis, R. J., Ginsberg, B., Hirsh, L., Sutter, D., Keith, S., McVey, E., Harvey, N. G., Hompesch, M., Nosek, L., Kapitza, C. & Heinemann, L. (2011). "Intradermal Microneedle Delivery of Insulin Lispro Achieves Faster Insulin Absorption and Insulin Action than Subcutaneous Injection," *Diabetes Technology & Therapeutics*, 13 (4) 435-442.

Polak, M., Beregszaszi, M., Belarbi, N., Benali, K., Czernikow, P. & Tubiana-Rufi, N. (1996). "Subcutaneous or Intramuscular Injections of Insulin in Children. Are We Injecting where We Think We are?," *Diabetes Care*, 19 (12) 1434-1436.

Rademecker, R. P., Pierard, G. E. & Scheen, A. J. (2007). "Lipodystrophy Reactions to Insulin: Effects of Continuous Insulin Infusion and New Analogs," *American Journal of Clinical Dermatology*, 8 (1) 21-28.

Selkow, N. M., Pietrosimone B. G. & Saliba S. A. (2011). "Subcutaneous Thigh Fat Assessment: A Comparison of Skinfold Calipers and Ultrasound Imaging," *Journal of Athletic Training*, 46 (1) 50-54.

Wallymahmed, M., Littler P., Clegg, C., Haqqani, M. T. & MacFarlane, I. A. (2004). "Nodules of Fibrocollagenous Scar Tissue Induced by Subcutaneous Insulin Injections: A Cause of Poor Diabetic Control," *Postgraduate Medicine Journal*, 80 (950) 732-733.