

IBIMA Publishing

Journal of Radiology Research and Practice

<http://www.ibimapublishing.com/journals/RADI/radi.html>

Vol. 2014 (2014), Article ID 145020, 11 pages

DOI: 10.5171/2014.145020



Research Article

Radiological Indices for Chest in the Indian Population

S .Allwyn Joshua¹, Lathika Shetty², Vidyashambhava Pare³, Sheela G Nayak⁴

and Roopa Sebastian⁵

^{1,3,4} Department of Anatomy, K V G Medical College, Sullia, India

²Department of Radiology, K S Hedge Medical Academy, Mangalore, India

⁵Department of Biochemistry, K V G Medical College, Sullia, India

Correspondence should be addressed to: S. Allwyn Joshua; oxfordjosh@yahoo.com

Received date: 9 December 2013; Accepted date: 15 February 2014; Published date: 6 May 2014

Academic Editor: Ahmet Emin Erbaycu

Copyright © 2014. S .Allwyn Joshua, Lathika Shetty, Vidyashambhava Pare, Sheela G Nayak and Roopa Sebastian. Distributed under Creative Commons CC-BY 3.0

Abstract

The thoracic skeleton is an osteocartilaginous frame which creates space for the principal organs of respiration and circulation. The present study aims at measuring the internal thoracic dimensions with focus on the manubriosternal joint angulation in individuals of different age groups, and provides a baseline value for internationally accepted vertebral and Haller's index in *Indian population*. **Methods and material:** 80 subjects with a chest considered to be morphologically normal on physical examination were studied. Non contrast Computed tomography images of chest were used to measure Manubriosternal joint angulation and internal dimensions like sterno-vertebral and transverse diameter. **Results:** Manubriosternal joint angulation in Pre-pubertal group had range of 160 to 168.9^o, and post pubertal group showed wider range of 154 to 178^o. Radiological indices like vertebral index showed a range of 16.26 to 20 with a mean of 17.82 in pre-pubertal group, and post-pubertal group showed a wider range of 15.4 to 25 with 19.9. Haller's index in pre-pubertal showed a negligible range with an average of 2.2, but the post-pubertal group showed an extensive range of 1.6 to 3.1 with average of 2.37. Sterno-vertebral distance in post pubertal group showed a mean of 100.4±17 (p<0.05) with range of 59 to 140 in comparison to pre-pubertal value of 79.7±14 (59 to 98) and the transverse distance in post-pubertal also showed significantly higher value of 230.2±26 (p<0.05), while pre-pubertal group showed average of 172±32. **Conclusion:** Alterations in the geometric dimensions and shape of the thoracic wall, change in the pattern and the mechanism of respiration are influenced not only due to change in the inclination of the rib and the curvature of the vertebral column, but also due to the position of the sternum plays a pivotal role.

Keywords: Manubriosternal joint (MSJT); Chest wall; Sterno-vertebral distance (sv); Haller's index (HI); Pectus deformity.

Cite this Article as: S .Allwyn Joshua, Lathika Shetty, Vidyashambhava Pare, Sheela G Nayak and Roopa Sebastian (2014), "Radiological Indices for Chest in the Indian Population", Journal of Radiology Research and Practice, Vol. 2014 (2014), Article ID 145020, DOI: 10.5171/2014.145020

Introduction

The thoracic skeleton is an osteocartilaginous frame which creates space for the principal organs of respiration and circulation. Intra-thoracic space is narrow above and broad below, flattened anteroposteriorly and longer behind (Datta, 1994). It is bound anteriorly by sternum, the rib cage forming the lateral wall and the vertebral column forming the posterior boundary (Williams, 2000). These three key components together form the frame work, giving oval contour to the thoracic wall in adults and rounded shape in infants (Openshaw, 1984). The primary function of the key components is to protect the vital organs like the lungs and the heart; they also contribute in the respiratory movements like bucket handle and pump handle movement where in rib and the sternum play an important role.

Intra-thoracic space has a limited area to accommodate numerous structures including heart, lungs and mediastinal structures. Openshaw (1984) and Haller (1987) explained about the alteration in the intra-thoracic space and its dimensions may be seen due to positional change of sternum in the front, ribs on the either side or vertebral column behind, as seen normally in the aging process from early infancy to adulthood or in the cases of anterior chest wall and spine deformities. According to Wachtel et al. (1956), compromise in the intra-thoracic space beyond a particular limit may compress upon the cardiac and lungs there by reducing the cardiac output and the lungs' volume especially during exercises. Chest wall deformities may be a disease in which different morphological types can be distinguished following morphological alterations of the sternum, the sterno-costal segments and the ribs (Willtal et al., 2011).

However, there are very limited data in the literature on the influence of the sternal position on thoracic shape. The present article would be the first of its kind in an

attempt to include the sternum as a key component in framing the thoracic shape and dimension. The aim was on the measurement of the internal thoracic dimensions in normal subjects with focus on manubriosternal joint angulation in individuals of different age groups so as to understand and differentiate the normal aging changes of the skeletal components with chest wall deformities; and finally an attempt to provide a baseline value for internationally accepted vertebral and Haller's index in Indian population so as to objectively categorise the chest wall as normal or deformed based on the findings.

Materials and Methods

The present study was conducted from September 2011 to August 2013 in two hospitals; K S Hegde medical academy, Mangalore and K V G Medical College and Hospital, Sullia. The study protocol was approved by the ethical committee of NITTE University in September 2011. Informed consent was obtained for the particular study. 80 subjects with a chest considered to be morphologically normal on physical examination were studied. Subjects were again divided into two groups:

Group 1: 36 subjects with age ranging from 1- 18 years with median age of 10 years (pre-pubertal group)

Group 2: 44 subjects with age ranging from 19- 40 years with median age of 25 years (post-pubertal group)

The criteria for inclusion of normal subjects were as follows:

- a) absence of depression or protrusion of the central portion of the anterior thoracic wall in relation to the costal cartilage during physical examination;
- b) CT scan of the thorax due to another type of clinical investigation;

- c) Age ranging from 1 to 40 years and patients excluded were with any affection that might interfere in the normal morphology of the thoracic cage (Rebies., 2007).

Radiological Indices

Non contrast Computerized tomography images of chest were assessed for more reliable data. For the measurement of angulation and dimensions, plain sagittal

midline view and axial section at the level of xiphisternal joint has been selected.

First, evaluating *manubriosternal joint position (MSJT)* A point on the upper end of the posterior border of manubrium, another on the posterior end of manubriosternal joint and a third point along the posterior border of body of sternum at the level of fourth costal notch. The posterior end of manubriosternal joint position (angulation) was determined by drawing lines to join the points marked on the plain sagittal section in CT [fig 1].

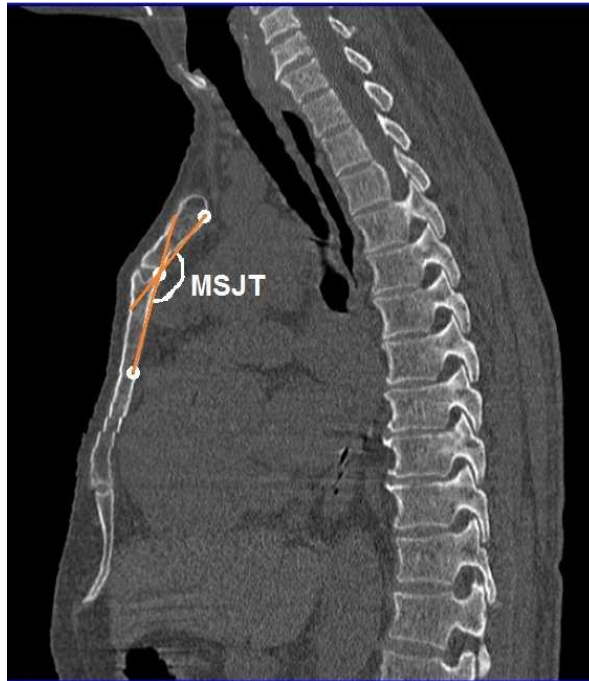


Figure 1: Non contrast CT image (sagittal view) of thorax showing the measurement of Manubriosternal joint angulation

Secondly, the *vertebral index (VI)* [fig 2]: is defined as the quotient of the vertebral sagittal diameter and the chest sagittal diameter from the anterior portion of the vertebral body to the posterior portion of the

sternum at xiphisternal junction (Klida, 2007, Luc Derveaux, 1989).

$$VI = \frac{V}{V+c} * 100$$

c – Sterno-vertebral distance, v – Vertebral Body length.

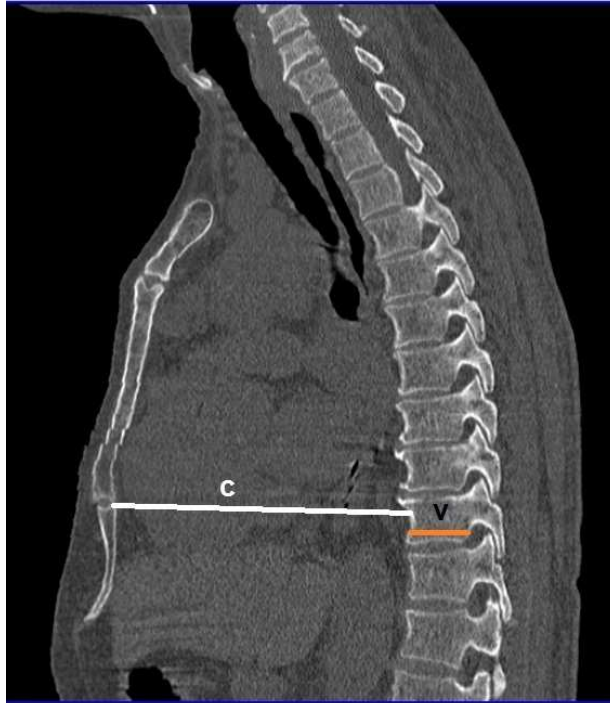


Figure 2: Non contrast CT image(sagittal view) of thorax showing the measurement of vertebral index

Thirdly, the Haller's index - It is the ratio between the horizontal distance of the inside of the ribcage and the shortest distance between the vertebrae and sternum at xiphisternal junction. It will be measured on axial CT images [fig 3].

$$HI = a/c$$

a - Transverse chest dimensions, c - Sterno-vertebral distance

Sterno-vertebral distance (c) and Transverse diameter of chest (a) measurements also were studied as separate entities and were analysed to study their influence on the internal thoracic dimensions in different age groups [fig 3].

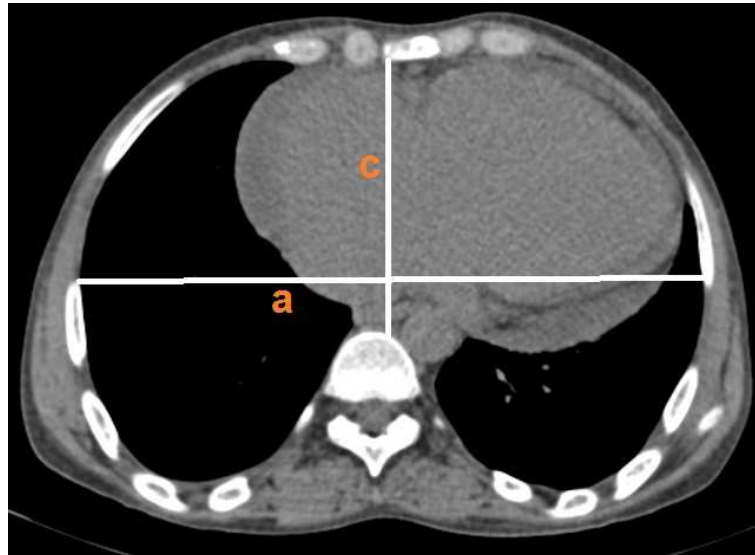


Figure 3: Non contrast CT image (transverse view) of thorax showing the measurement of haller's index

Statistical Analysis

The values measured have been depicted as mean \pm standard deviation. Significance was calculated with *student t test* at 95% confidence; and the correlation between Manubriosternal joint angulation and sterno-vertebral distance, as well as correlation between Manubriosternal joint angulation and transverse diameter of chest was done using *Pearson's correlation*. Box-whisker plot

has been used to depict manubriosternal joint range. Scatter graph with trendline has been used to depict correlation between the radiological indices, and bar graph has been used to show the values of all the indices; MSJT, VI, HI sterno-vertebral and transverse diameter in the pre and post pubertal group. Data were analysed using excel and SPSS software.

Results

Table 1: Comparison of Radiological indices between pre-pubertal and post-pubertal in controls

Groups	Values	MSJT (°)	VI (%)	HI	Sv (mm)	a (mm)
Pre-pubertal group	Mean	165.3167	17.82	2.245	79.766667	172.1167
	SD	3.092194	1.27419	0.12661	14.185439	32.07431
	MIN	160	16.26	2.04	59.5	121.8
	MAX	168.9	20	2.41	98	203

Table 1: Comparison of Radiological indices between pre-pubertal and post-pubertal in controls

Groups	Values	MSJT(°)	VI (%)	HI	Sv (mm)	a (mm)
Post-pubertal group	Mean	165.6125	19.93219	2.379375	100.49688*	230.2188*
	SD	5.993585	2.594403	0.333108	17.070451	26.79768
	MIN	154	15.4	1.66	59.5	121.8
	MAX	178.1	25	3.1	140.9	263.3

*Indicates significance using student t test at 95% confidence interval

Table 1 shows the mean, standard deviation, minimum and maximum values of MSJT, VI, HI and internal dimensions like sterno-vertebral and transverse diameter. Comparison of Manubriosternal angulation between the pre-pubertal and post-pubertal showed almost the same mean value of 165 ± 3 and 165 ± 5 degree. Pre-pubertal group had range of 160 to 168.9° and post pubertal group had a wider range of 154 to 178° . Radiological indices like vertebral index showed a range of 16.26 to 20 with a mean of 17.82 in pre-pubertal group, and post-pubertal group showed a wider range of 15.4 to 25 with 19.9 which was not significant on comparison. Haller's index in pre-pubertal showed a negligible range with an average of 2.2, but the post-pubertal group showed an extensive range of 1.6 to 3.1 with an average of 2.37, Haller index did not show significant difference between both groups. The only notable feature with the three indices was

the range indicating the minimum and the maximum values showed a wider range in post-pubertal group in comparison to pre-pubertal age group. Internal dimension like sterno-vertebral distance (sv) and transverse diameter (a) showed significant difference between both groups. Sterno-vertebral distance in post pubertal group showed significantly higher mean of 100.4 ± 17 ($p<0.05$) with a range of 59 to 140 in comparison to pre-pubertal value of 79.7 ± 14 (59 to 98), and the transverse distance in post-pubertal also showed significantly higher value of 230.2 ± 26 ($p<0.05$), while pre-pubertal group showed average of 172 ± 32 .

The range of manubriosternal joint angulation in pre pubertal as well as post pubertal group shows median value of 165.4° , with lower limit of 161° and higher limit of 178° [fig 4]

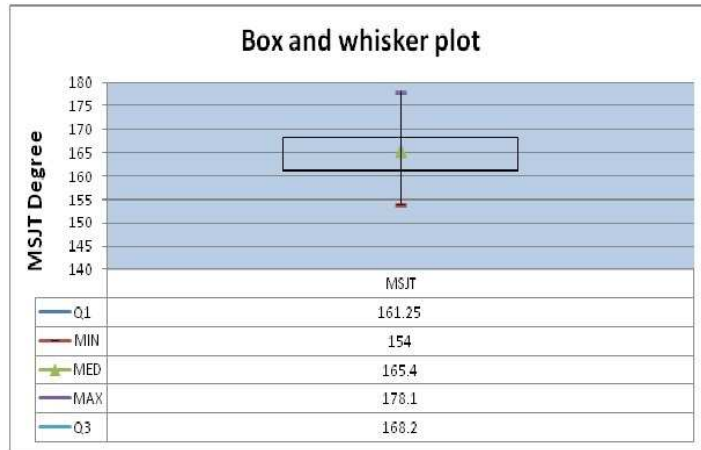


figure 4: shows the range of manubriosternal joint angulation.

Values like MSJT angulation, sterno-vertebral distance and transverse diameter have been represented in a bar graph plot [fig 5],

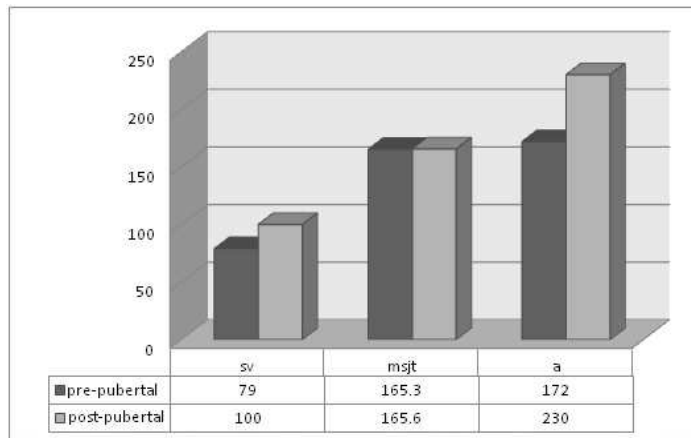


Figure 5: Bar graph plot indicating the range of manubriosternal, sterno-vertebral and transverse diameter of chest in both groups

here the sterno-vertebral distance and transverse diameter showed significant difference in the post-pubertal group mainly due to the pubertal growth spurt. Weak

negative correlation ($r = -0.21$) was seen between MSJT angulation and sterno-vertebral distance with both groups [Fig 6].

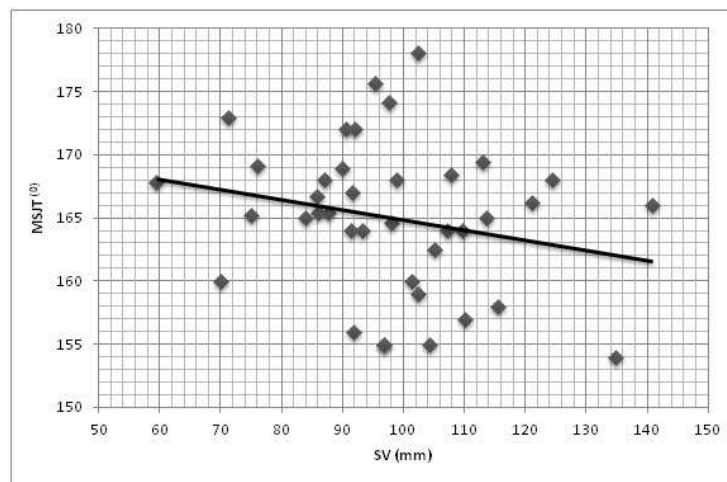


Figure 6: Correlation between Manubriosternal joint and sterno-vertebral distance

MSJT angulation and sterno-vertebral distance in [fig 7]

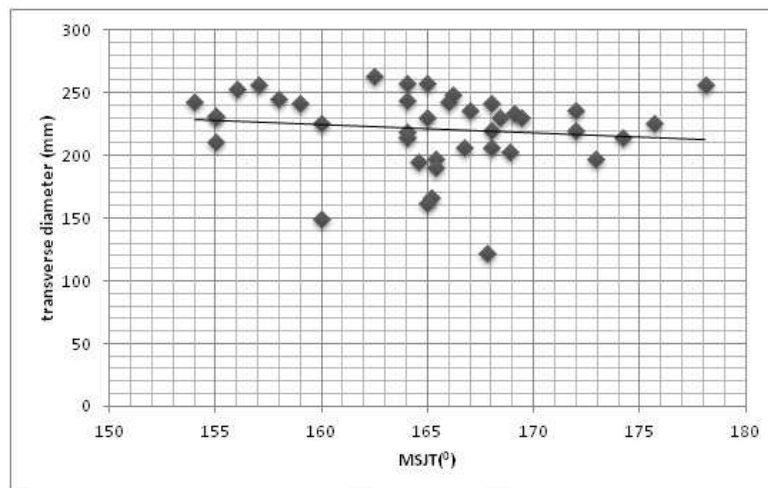


Figure 7: showing Correlation between Manubriosternal joint angulation and transverse diameter

both groups showed no significant correlation ($r = -0.11$). Strong positive and significant correlation ($r = 0.56$) was seen

between transverse diameter and sterno-vertebral distance [Fig 8].

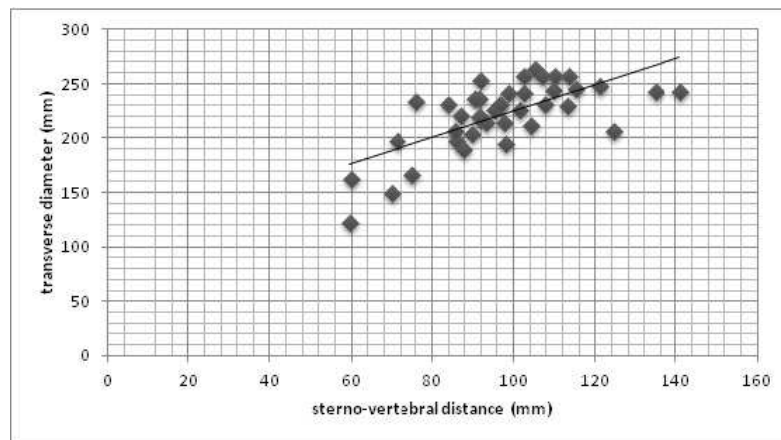


Figure 8: showing correlation between transverse diameter and sterno-vertebral distance

Discussion

Since changes of chest wall constitute the main anatomical component of chest wall deformities, radiological chest examination enables the assessment of chest condition, deformation, degree and shape. It also allows planning the operation, predicting its results and treatment outcome (Haller, 1987). Computed tomography has become a very useful tool in current diagnostics with an advantage of repeatability and the possibility of high resolution and multi-dimensional images (especially including bone structures), enabling measurements in unlimited planes (Given et al 2004, Grimby et al., 1968 and Howard., 1949). To our knowledge, internal thoracic dimension measurement in the Indian population has not been investigated so far, either with traditional radiograms or with the use of computed tomography.

Manubrium and the body of sternum along with the ribs and the vertebral column are among the key components, which provide chest the contour, which was rounded during infancy and changes to oval or reniform shape in adults (Openshaw, 1984). Apart from the positional variation of sternum during the normal aging process of chest wall, even during the development of pectus anomalies the sternum is usually regarded as the culprit. The advocates of this hypothesis

believe that the displacement of the sternum occurs first, followed by changes in the costal cartilages, which have no option but to follow the sternum in its displaced position. In Pectus excavatum, sternal depression usually begins at the junction of the manubrium and sternum (gladiolus) and becomes progressively deeper toward the xiphoid process. The costal cartilages are elongated, distorted, and sometimes fused together. If the sternum is pushed inward, the result is pectus excavatum, if it is pushed outward, pectus carinatum develops (Francis et al., 1974).

With the evidence supporting the importance and involvement of manubriosternal joint in normal and deformed chest wall, we have begun by measuring the joint angulation in individuals with normal chest wall, so as to provide a baseline range for manubriosternal joint angulation in two important age groups, pre-pubertal and post-pubertal age groups. Scanty yet vital literature was retrieved to support the present article; the article by Constantine (1974), measuring the Manubriosternal joint movements during respiration in young athletes which showed an angulation of 165.30 ± 7.19 in females, 166.35 ± 7.38 in males. Our reports showed a range of 155 – 175 ($^{\circ}$) and average of 165 ($^{\circ}$) in controls, manubriosternal joint angulation in children (pre-pubertal) and adults (post-

pubertal group) showed almost similar angulation, indicating the early positioning between manubrium and sternbrae which remains unaltered with aging except in conditions with affected chest wall such as pectus carinatum and excavatum (Willtal, 2011). Manubriosternal joint angulation between both sexes showed almost similar values which was not significant.

Change in the manubriosternal joint angulation does alter the internal thoracic dimensions. To understand the influence of the positional variation of the manubriosternal joint on chest wall, components of internal thoracic dimensions like sterno-vertebral distance and transverse diameter were included. As the four sternbrae fuse to form a single body of sternum, the position of manubrium in relation to first sternbrae usually remains unaltered, but the lower portion of the body of sternum changes from convex forwards to a straight segment, gives a better understanding of the change in the shape of thoracic wall in adults when compared to children; thoracic wall in pre-pubertal age undergoes changes in a slower pace until pubertal growth spurt. There was a positive correlation between the two components, i.e. increase in sterno-vertebral distance also changes the transverse diameter of the chest wall.

Radiological indices like vertebral index and Haller's index was also included in the present report so as to complete the overall involvement of all the components forming and affecting the contour, shape of the chest wall and its dimensions. In the present study, internationally accepted Haller's index and vertebral index were measured in individuals with normal chest contour, so as to provide the range to classify or categorize the chest wall as normal or deformed, and if deformed to classify it as mild, moderate or severe deformed chest wall. Haller's index showed wider range of 1.6 to 3.1 with mean of 2.3 in post pubertal group and vertebral index around 15.4 to 25 with average of 19% in subjects whose chest wall contour was normal on physical examination. Haller et al

(1987) have mentioned that the severity of the pectus deformity can be assessed by the pectus index. A pectus index greater than 2.5 is significant and an index greater than 3.2 is generally regarded as a severe deformity. Klida et al (2007) has mentioned about the pre-operative CT and x ray assessment of chest deformation and has provided radiological indices ; $VI \geq 26$, $HI \geq 3.1$ as the indications for the surgical corrections .

This study has provided base line values for important radiological indices like sterno-vertebral distance, transverse diameter, Vertebral Index and Haller's Index, so as to objectively categorise chest wall as normal or deformed based on the findings in the Indian population.

To conclude, alterations in the geometric dimensions and shape of thoracic wall, change in the pattern and the mechanism of respiration are influenced not only due to change in the inclination of the rib and the curvature of the vertebral column, even the position of the sternum plays a pivotal role. Awareness of the basic anatomical changes in the thoracic wall and respiratory physiology with aging would help clinicians in better understanding and interpreting the deformity, thereby differentiating between the normal changes of an aging chest and the chest wall deformation.

Conflict of interest: none declared

References

1. Constantinescu, A. (1974). "Biomechanical Study on Joint Range of Motion of Manubriosternal joint in adults". *Arch Ana*, 57:153-199
2. Datta, A K. (1994). "Essentials of human anatomy. Thorax and abdomen". 3rd edn. Current Books International, Calcutta, pp 80-86.

3. Francis Robicsek, Harry, K. Daugherty, Donald, C. Mullen. (1974) "Technical Considerations in the Surgical Management of Pectus Excavatum and Carinatum". *Ann thorac surg*; volume 18: number 36
4. Givens, M.L. Ayotte, K. Manifold, C. (2004). "Needle thoracostomy: implications of computed tomography chest wall thickness". *Academic Emergency Medicine* 11(2): 211-213
5. Grimby, G. Bunn, J. Mead, J. (1968). "Relative contribution of rib cage and abdomen to ventilation during exercise". *J Appl Physiol.* 24:159-166.
6. Haller, J A. Kramer, S S. Lietman, A. (1987). Use of CT scans in Selection of Patients for Pectus Excavatum Surgery: A preliminary report. *J Pediatr Surg*; 22:904-906
7. Howard, P. Bauer, A. (1949). "Irregularities of breathing in the newborn period". *Am J Dis Child* 77:592-609
8. Kilda, A. Basevicius, A. Barauskas, A. (2007). "Radiological assessment for the children with pectus excavatum. *Indian j. pediatric* , feb;74(2);143-7
9. Luc Derveaux, Ignace Clarysse. (1989). "Preoperative and Postoperative Abnormalities in Chest X-ray indices and in Lung Function in Pectus Deformities". *Chest journal*;95:850-56
10. Openshaw, P. Edward, S. Helms P. (1984). "Changes in rib cage geometry during childhood". *Thorax* 39:624-627
11. Rebeis, E B. Campos, J R. Fernandez, A. Moreira, L F. Jatene, F B. (2007). "Anthropometric index for pectus excavatum". *Clinics*, 62 (5):599-606
12. Wachtel, F W. Ravitch, M M. Grishman, A. (1956). "The relation of pectus excavatum to heart disease". *Am Heart J*; 52: 121-37.
13. Willital, G.H., Saxena, A.K., Schütze, U, Richter W. (2011). "Chest-deformities: a proposal for a classification". *World J Pediatr* ;7(2):118-123
14. Williams, L. (2000). "Gray's anatomy, 38th Edn. Chrchill Livingstone", pp 510-45