



Research Article

Is there Any Relationship between Allergic Rhinitis and Concha Bullosa?

Turhan San¹, Deniz Hanci², Nuray Bayar Muluk³ and Cemal Cingi⁴

¹Istanbul Medeniyet University, Göztepe Training and Research Hospital, ENT Department, Istanbul, Turkey

²Liv Hospital, ENT Department, Istanbul, Turkey

³Kırıkkale University, Faculty of Medicine, ENT Department, Kırıkkale, Turkey

⁴Eskisehir Osmangazi University, Faculty of Medicine, ENT Department, Eskisehir, Turkey

Correspondence should be addressed to: Turhan San; turhansan@gmail.com

Received Date: 30 March 2014; Accepted Date: 4 June 2014; Published Date: 24 June 2014

Academic Editor: Erkan Tarhan

Copyright © 2014 Turhan San, Deniz Hanci, Nuray Bayar Muluk and Cemal Cingi. Distributed under Creative Commons CC-BY 3.0

Abstract

Concha bullosa (CB) is the pneumatization of intranasal turbinates. It is most commonly seen in the middle turbinate. The formation mechanism of CB is not fully elucidated so far. It is well known that allergic rhinitis (AR) affects the mucosa of intranasal structures and eventually these structures become edematous. The aim of this study was to investigate the presence of CB retrospectively in patients with AR.

The method used is to determine the presence of CB, paranasal sinus computed tomography (PNSCT) scans of 45 patients (25 females, 20 males) with AR were examined. The PNSCT sections showing maxillofacial fractures, sinonasal neoplasms and the results of previous surgeries were not included into the study.

CB was observed in 25 of 45 patients with AR (55.5%). 7 of these 25 patients had unilateral (28%), while 18 had bilateral (72%) CB. All the patients had the middle turbinate pneumatization. There was no significant correlation between side of the CB (unilateral or bilateral) and gender and age.

CB is a common anatomic variation in patients with AR and this contributes to the severity of symptoms. CB makes nasal obstruction much worse in AR patient, and may cause rhinosinusitis besides contact headaches. In the present study, coexistence of CB was detected as 55.5% with AR. In case of non-symptomatic CB, there is no need for additional treatments. However, in symptomatic cases, removal of the lateral lamella of the middle turbinate should be performed.

Keywords: Allergic rhinitis, concha bullosa, paranasal sinus computed tomography (PNSCT).

Introduction

The pneumatization of middle turbinate has been called as concha bullosa (CB). It is usually asymptomatic, but it sometimes can cause different sinonasal symptoms. The severity of symptoms is related to degree of pneumatization.

Allergic rhinitis (AR) is asymptomatic disorder of the nose induced after allergen exposure by an immunoglobulin E (IgE)-mediated inflammation (Bousquet et al, 2001). AR affects 10–30% of the population, with the greatest frequency found in children and adolescents (Sih and Mion, 2010).

In Sedaghat et al's (2012) study, infraorbital (Haller) cells, CB, frontal intersinus cells, and anterior ethmoid frontal recess cells were evaluated in coronal paranasal sinus computed tomographies. They reported that infraorbital and frontal intersinus cells are associated with development of chronic rhinosinusitis (CRS) in patients with AR.

Until now, CB has related to nasal septum deviation and sinusitis (Uygur et al, 2003; Ural et al, 2010). There was no study about the relationship between CB and AR. Here, our aim was to investigate the presence of CB in patients with AR.

Material and Methods

This retrospective study was carried out in ENT Department of Istanbul Medeniyet University, Göztepe Training and Research Hospital according to the principles outlined in Helsinki Declaration (2008).

Subjects

Present study was designed retrospectively and consisted of 45 patients (25 females, 20 males) with AR who were previously diagnosed according to the skin prick test results.

A skin prick test that involved the most common regional environmental antigens was applied to each participant previously. Histamine and saline solutions were used

as positive and negative controls, respectively. The resulting "wheal and flare" reactions were evaluated 10 min after the application. Each reaction wider than 3 mm in diameter was regarded as a positive result. Each participant who developed at least one positive reaction against an antigen was evaluated as an allergic individual.

Paranasal sinus computed tomography (PNSCT) sections showing maxillofacial fractures, sinonasal neoplasms, sinonasal polyps and patients with previous surgery were not included into the study. None of the AR patients was concurrent with diagnosed asthma.

Paranasal Sinus Computerized Tomography (PNSCT) Evaluation: To detect the presence of CB, the coronal plane paranasal sinus CT scans of the patients with AR were examined. PNSCTs were taken for a various reasons, such as headache and nasal obstruction. The Paranasal Sinus Computerized Tomography (PNSCT) archive of the first author (TS) was used as retrospective data source of this study for the measurement. The PNSCTs were obtained from General Electric Optima 660 (USA) machine 64x2 = 128 slices and with Toshiba Activation (Japan) machine as 16 slices.

Statistical Analysis

All study data were evaluated using the SPSS version 16.0 software. The Chi-square test and Spearman's correlation rho efficient test were used.

A $p < 0.05$ was accepted as indicative of a significant difference.

Results

A total of 45 patients with AR were included in this study. The mean age of the patients with was 39.5 years (range 15-74 years).

Of these 45 patients with AR, CB was present in 25 patients (55.5%). The mean age of patients with CB (14 females and 11 males) was 36.3 ± 16.3 years (range 15-

74).Seven of these 25 (7/25) had unilateral (28%) (Figure 1); however 18 of them (18/25) had bilateral (72%) CB (Figure 2).All of the patients had the middle turbinate pneumatization, whereas superior and inferior turbinate

pneumatization was not seen.CB was not detected in 20 patients (45.5%). The mean age of the patient with AR without CB(11 females and 9 males) was 43.6 ± 14.7 years (Ranged from 17.0 to 71.0).

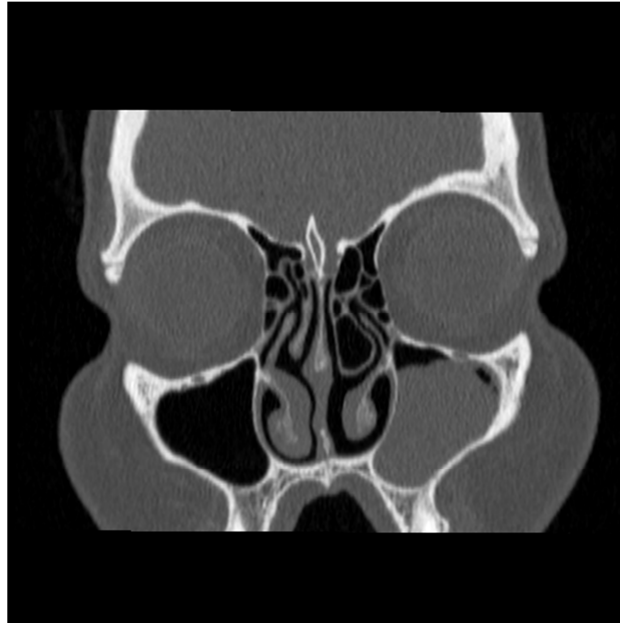


Figure 1: Coronal Paranasal Sinus Computed Tomography View for Left Unilateral Concha Bullosa

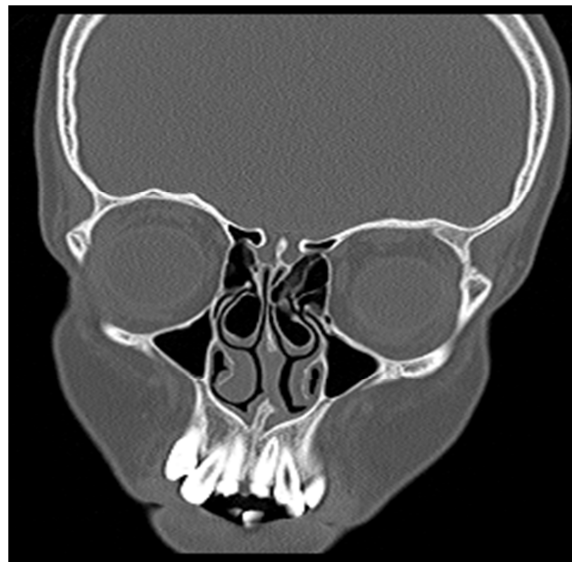


Figure 2: Coronal Paranasal Sinus Computed Tomography View for Bilateral Concha Bullosa

Gender of the AR patients with CB were shown on Table 1. There is no significant difference between gender of the patients

and unilateral or bilateral CB by Chi-Square test ($p=0.419$, $X^2=0.654$).

Table 1: Gender of the Allergic Rhinitis Patients with Concha Bullosa

		Unilateral Concha Bullosa		Bilateral Concha Bullosa		Total		p
		n	%	n	%	n	%	
Gender	Male	4	36.4	7	63.6	11	100.0	P=0.419 X ² =0.654
	Female	3	21.4	11	78.6	14	100.0	
	Total	7	28.0	18	72.0	25	100.0	

*p value shows the results of Chi-Square test

The relationship between gender, age and side of the CB (Code 1: Unilateral, Code 2: Bilateral) was analyzed by the results of Spearman's correlation rho efficient test

(Table 2). There was no significant correlation between side of the CB, gender and age.

Table 2: The Results of Spearman's Correlation Rho Efficient Test

		Gender	Age	Concha Bullosa (Code 1: Unilateral, Code 2: Bilateral)
Gender	r		-0.257	0.165
	p		0.214	0.430
Age	r	-0.257		-0.087
	p	0.214		0.681
Concha Bullosa (Code 1: Unilateral, Code 2: Bilateral)	r	0.165	-0.087	
	p	0.430	0.681	

Discussion

CB is a very common variation in normal population. CB is usually seen in the middle turbinate (Unlu et al, 1994; Bolger et al, 1991). There are few theories for its occurrence: (1) Expansion of sinus pneumatization into the turbinate during intrauterine period (Yang et al, 2008), (2) Fusion abnormality during intrauterine development, (3) Conchal bone microfractures during late puberty causing nasal mucosal invagination expanding to bullosa cavity and eventual CB development (Peric et al, 2010; Dogru et al, 1999).

In the present study, we investigated the presence of CB in patients with AR. CB was present in 55.5% of patients with AR. It was either unilateral (28%) or bilateral (72%). In CB cases, there was only middle turbinate pneumatization. There was no correlation between side of the CB (unilateral or bilateral) and gender and age.

Our results showed that there is a high rate coexistence of 55.5% between AR and CB.

In Unlu et al's (1994) and Bolger et al's studies (1991), the incidence of CB was 13% and 53%. Anterior and posterior ethmoidal cells are responsible for pneumatization of CB (Unlu et al, 1994; Bolger et al, 1991). After the formation of septum deviation, the air flow pattern of nasal cavity on the opposite side of the deviation provokes the development of CB (Stammberger et al., 1991). Whereas according to Uygur et al., CB incidence doesn't increase with septal deviation (Uygur et al, 2003).

AR comorbidities are asthma, middle ear effusion, rhinosinusitis, lymphoid hypertrophy with obstructive sleep apnea, etc. (Lack, 2001). In Smith et al's study (2010), there was pneumatization of at least one concha (67.5%), septal deviation (19.4%) and mucosal thickening and maxillary rhinosinusitis (50.0%) with AR. In 49.3% of the patients, there were CB and maxillary sinusitis.

CB may cause nasal congestion and sinusitis (Caughey et al, 2005). CB makes

nasal obstruction much worse in AR patient, and may cause rhinosinusitis besides contact headaches. In the present study, coexistence of CB was detected as 55.5% with AR. However, Bolger *et al.* (2001) reported that lamellar, bulbous and extensive concha bullosa were detected in 46.2%, 31.2% and 15.7% of CT images respectively.

In patients with CB, removal of the lateral lamella of the middle turbinate should be performed. In AR patients with nasal obstruction, presence of coincidental CB should be considered.

Conclusion

In patients with AR, coincidence of CB should be kept in mind. Especially in AR patients with nasal obstruction; or contact headache, CB should be investigated by PNSCT.

Acknowledgement

"With the exception of data collection, the preparation of this paper, including design and planning, was supported by the Continuous Education and Scientific Research Association."

References

Bolger, W. E., Parsons, D. S. & Butzin, C. A. (1991). "Paranasal Sinus Bony Anatomic Variations and Mucosal Abnormalities: CT Analysis for Endoscopic Sinus Surgery," *Laryngoscope*, 101 (1 Pt 1) 56-64.

Bousquet, J., Van Cauwenberge, P. & Khaltaev, N. (2001). "Allergic rhinitis and its Impact on Asthma," *Journal of Allergy and Clinical Immunology*, 108 (Suppl. 5) S147-S334.

Caughey, R. J., Jameson, M. J., Gross, C. W. & Han, J. K. (2005). "Anatomic Risk Factors for Sinus Disease: Fact or Fiction?," *American Journal of Rhinology* 19 (4) 334-339.

Dogru, H., Doner, F., Uygur, K., Gedikli, O. & Cetin M. (1999). "Pneumatized Inferior

Turbinate," *American Journal of Otolaryngology* 20 (2) 139-141.

Lack, G. (2001). "Pediatric Allergic Rhinitis and Comorbid Disorders," *Journal of Allergy and Clinical Immunology* 108 (1 Suppl) S9-15.

Peric, A., Baletic, N. & Sotirovic, J. (2010). "A Case of an Uncommon Anatomic Variation of the Middle Turbinate Associated with Headache," *ACTA otorhinolaryngologica italica* 30 (3) 156-159.

Sedaghat, A. R., Gray, S. T., Wilke, C. O. & Caradonna, D. S. (2012). "Risk Factors for Development of Chronic Rhinosinusitis in Patients with Allergic Rhinitis," *International Forum of Allergy & Rhinology* 2 (5) 370-5.

Sih, T. & Mion, O. (2010). "Allergic Rhinitis in the Child and Associated Comorbidities," *Pediatric Allergy and Immunology* 21(1 Pt 2) e107-13.

Smith, K. D., Edwards, P. C., Saini, T. S. & Norton, N. S. (2010). "The Prevalence of Concha Bullosa and Nasal Septal deviation and Their Relationship to Maxillary Sinusitis by Volumetric Tomography," *International Journal of Dentistry* 2010. pii: 404982. Epub 2010 Aug 24.

Stammberger, H. (1991). 'Endoscopic and Radiologic Diagnosis,' In: Stammberger H, editor. Functional Endoscopic Sinus Surgery: The Messerklinger Technique. 1st ed. Philadelphia: BC Decker; p. 145-273.

Unlu, H. H., Akyar, S., Caylan, R. & Nalca, Y. (1994). "Concha Bullosa," *The Journal of Otolaryngology* 23 (1) 23-27.

Ural, A., Kanmaz, A., Inançlı, H. M. & Imamoğlu, M. (2010). "Association of Inferior Turbinate Enlargement, Concha Bullosa and Nasal Valve Collapse with the Convexity of Septal Deviation," *Acta Otolaryngologica* 130 (2) 271-4.

Uygur, K., Tüz, M. & Doğru, H. (2003). "The Correlation between Septal Deviation and Concha Bullosa," *Otolaryngology--Head and Neck Surgery* 129 (1) 33-36.

WMA (2008). "Declaration of Helsinki. Ethical Principles for Medical Research Involving Human Subjects," in *59th WMA General Assembly, W. M. Association*, Editor: Seoul.

Yang, B. T., Chong, V. F. H., Wang, Z. C., Xian, J. F. & Chen, Q. H. (2008). "CT Appearance of Pneumatized Inferior Turbinate," *Clinical Radiology* 63 (8) 901-905.