



Research Article

Quantitative Studies of the Evolution of Diabetic Foot Lesions under EGF Treatment by Magnetic Resonance Imaging

Carlos Cabal-Mirabal¹, Evelio González Dalmau¹, Jorge Berlanga Acosta¹, Daniel Darias Zayas¹, Luis Herrera Martínez¹, Pedro Lopez Saura¹, Gerardo Guillén Nieto¹, Julio Baldomero Hernández¹, Carlos González Delgado² and Luis Javier González¹

¹Center for Genetic Engineering and Biotechnology (CIGB), Cubanacán, Playa, Havana, Cuba

²National Centre for Toxicology Havana, Cuba

Correspondence should be addressed to: Carlos Cabal-Mirabal; carlos.cabal@cigb.edu.cu

Received Date: 25 February 2014; Accepted Date: 15 May 2014; Published Date: 30 June 2014

Academic Editor: Martin Teraa

Copyright © 2014 Carlos Cabal-Mirabal, Evelio González Dalmau, Jorge Berlanga Acosta, Daniel Darias Zayas, Luis Herrera Martínez, Pedro Lopez Saura, Gerardo Guillén Nieto, Julio Baldomero Hernández, Carlos González Delgado and Luis Javier González. Distributed under Creative Commons CC-BY 3.0

Abstract

The Diabetic Foot (DF) is a very complex entity, and the imaging feet studies are an actual problem. The purpose of this work is to obtain new quantitative information by Magnetic Resonance (MR) for the evaluation of the DF Ulcers (DFU) during treatment.

The procedure was set up with ten healthy volunteers' feet. MR studies of ten DFU patients were done previously and during epidermal growth factor (EGF) treatment. DFU size (area and volume) variations, edema volume changes, as well as the water apparent diffusion coefficient (ADC), and metabolites changes, were determined at different times by MR.

MR Imaging (MRI) and Spectroscopy (MRS) provide new quantitative evidences related to the healing process. Decrease in injured area and volume, reduction of edema volume, and trend seen in ulcer ADC towards values seen in healthy zones, are all useful to characterize the DF response to therapy, and could be used in practice as status and evolution markers. Comparing the amplitude of MRS lines during treatment may also provide additional metabolic information.

This MRI/MRS reported procedure might be also useful for evolution studies of other pedal disorders, for example, those associated with wounds, inflammatory processes, and tissues changes.

Keywords: MRI; Diabetic Foot Ulcer; Quantitative evaluation.

Cite this Article as: Carlos Cabal-Mirabal, Evelio González Dalmau, Jorge Berlanga Acosta, Daniel Darias Zayas, Luis Herrera Martínez, Pedro Lopez Saura, Gerardo Guillén Nieto, Julio Baldomero Hernández, Carlos González Delgado and Luis Javier González (2014), "Quantitative Studies of the Evolution of Diabetic Foot Lesions under EGF Treatment by Magnetic Resonance Imaging," *Journal of Radiology Research and Practice* Vol. 2014 (2014), Article ID 783980, DOI: 10.5171/2014.783980

Introduction

Available published research comparing imaging modalities of pedal disorders highlight the technical difficulties involved, and point to magnetic resonance imaging (MRI) as one of the best choices, due its non-invasive nature, and the high spatial resolution and contrast that can be obtained (Schmid et al., 2002, Frykberg 2006, Johnson & Collins 2009, Vartanians et al., 2009, Sanverdi & Ergen 2012, Viswanathan 2013).

MRI published studies of pedal pathologies have mainly been qualitative. Quantitative and serial (longitudinal) evaluations using MRI in these disorders have seldom been carried out, being the investigation of muscle atrophy in neuropathic diabetes by Andreassen et al., 2009, and that of subcutaneous and inter and intraosseous edema changes in time in multistage ultra-marathoners (Freund et al., 2012) among the very few published examples.

The current paper describes the results of a quantitative MRI study that evaluates diabetic foot ulcer (DFU) patients under treatment. The purpose of this investigation was to set up the methodologies necessary for the study of this complex pathological scenario, and to produce evidence supporting the previously reported therapeutic action of intralesional epidermal growth factor (EGF) (Berlanga et al., 2006).

The DFU size (area and volume) variations, edema volume changes, as well as the water Apparent Diffusion Coefficient (ADC), and metabolites changes in the ulcer environment, were determined at different times, previously and after the treatment, by MRI and spectroscopy (MRS).

Materials and Methods

Study Subjects: The present study was reviewed and approved by the Ethics Committee of the Medical-Surgical-Research Center (CIMEQ) according to the ethical principles of the World Medical Association (Declaration of Helsinki). Written informed consent was obtained

from all 10 no diabetic healthy volunteers and 10 DFU patients (6 neuropathic and 4 ischemic) before their inclusion. This cohort included lesions classified as grades I or II by the Wagner scale (Frykberg 2006).

Magnetic Resonance Sequences: MRI examination was performed with a 1,5 T Symphony Master Class system (Siemens, Germany). The sequences used were T1 Spin Echo (coronal, axial and sagittal) with Echo Time (TE) and Repetition Time (TR) 12 ms and 478 ms, respectively. The Short Tau Inversion Recovery (STIR) images were performed with TR = 4800 ms, TE = 45ms and Inversion Time (TI) = 150 ms. In all cases the slice thickness was 3 mm, and the inter slices gap was zero mm. The Diffusion Weighted Images (DWI) were registered by Single Shot Echo Planar Imaging (SSEPI) sequence for five b values (0, 100, 300, 500 and 750 s/mm^2), TE= 85ms; TR= 8000 ms, slice thickness 6 mm and, inter slice gap 0, 6 mm. The ADC values were calculated from the DWI by Matlab. 7. x software. "In vivo" 1H MRS were obtained using a single voxel (1 cm^3) localized in the ulcer region and in the equivalent region of the corresponding contralateral healthy foot.

A MR study of 10 DFU patients was done before and during the intralesional epidermal growth factor (EGF) treatment, at least in three different moments (one before and two during the treatment), in dependence of the particular behavior of each patient, until the lesion had totally closed (Berlanga et al., 2006, Lopez -Saura et al., 2013).

Image Storage and Processing: MRI data were stored and processed in DICOM format in a database using eFilm 2.x. The areas and volumes calculations were performed manually using Amira 5.1.0 and Matlab. 7. x. The existence of statistically significant differences between the values obtained for each volunteer and patient was examined with an ANOVA-test for normally distributed data of homogeneous variance. Statistical significance was set at $p < 0.05$. For each healthy volunteer, the variation coefficient for calcaneus

areas was calculated in base of the areas measurements at two different time points (See Table I). The statistical analysis was also implemented using Matlab 7.x.

Positioning and Fixing the Feet: A device was designed to be placed in the head radiofrequency coil of the standard configuration of the equipment in order to

guarantee the reproducibility of the feet positioning. The device provides two affixed sets of external markers as a foot position reference. Figure 1 A-C shows MRI scans of a healthy volunteer's feet, showing the parallel markers (identified with arrows) in coronal (A) and sagittal (B) slices as well as a three dimensional (3D) reconstruction (C).

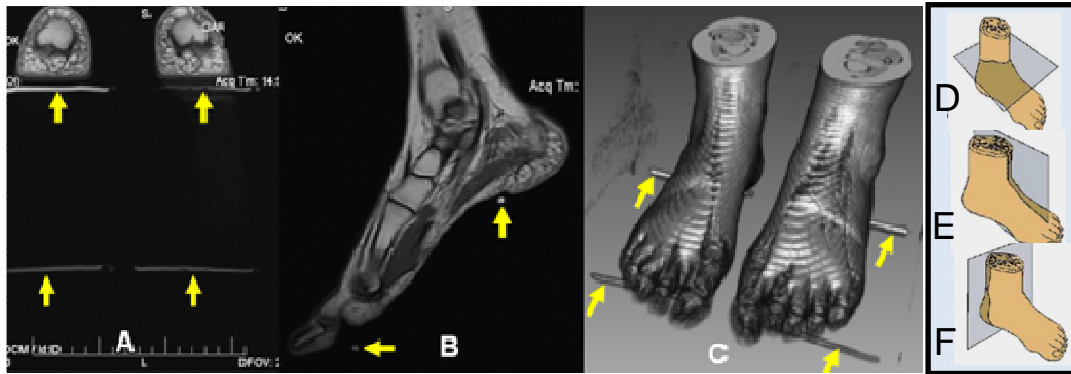


Fig. 1: MRI of the Feet of a Healthy Volunteer. The External Markers are Identified Using Arrows. (A) Coronal Slice; (B) Sagittal Slice; (C) 3D Reconstruction. D-F Show the Coronal (D) Sagittal (E) and Axial (F) Selected Orientations.

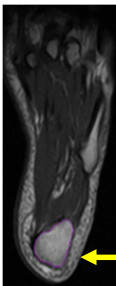
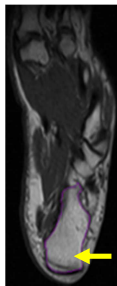
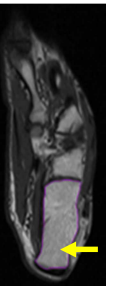
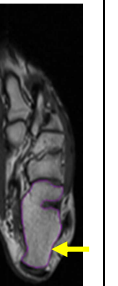
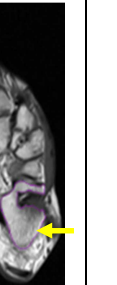
The coronal slice was the first to be registered (Fig. 1 D) parallel to the foot sole and to the plane defined by the external markers. The other two slices (axial and sagittal) were selected to be strictly orthogonal to the first one (Fig. 1 E, F).

Fixing both feet at the same time allows simultaneous MRI images without changes in the experimental conditions, with each foot serving as a reference of the other.

The calcaneus area was selected as an internal marker to evaluate the positioning

error. The measured areas values obtained are highly dependent on the foot position and on the MRI slice orientation. Table 1 shows the variation of the mean area measurements from 5 different coronal slices of the calcaneus of the ten healthy volunteers, at different time points. The maximum mean difference of the areas ratio, from one measurement to another, was less than 4.5% in all cases. Any change larger than 5% was thus assumed to represent the result of a physiological or pathological event.

Table 1: Variation Coefficient for Calcaneus Areas Calculated for Ten Healthy Volunteers in Five Different Coronal Slices, at Two Different Time Points. The Maximum Variation is Less than 4.5%

Different slices from the Calcaneus						
Coefficient of variation in % (10 volunteers)	1	0,86	1,48	0,54	1,21	1,32
	2	0,15	0,08	0,48	0,57	1,03
	3	1,81	0,10	0,10	0,36	0,03
	4	1,56	4,35	2,67	0,52	2,11
	5	2,65	0,27	0,11	0,78	1,65
	6	0,66	0,56	0,16	1,06	0,08
	7	2,78	0,23	0,45	0,59	0,62
	8	0,72	2,08	0,90	2,90	4,40
	9	1,45	1,61	0,43	1,68	0,95
	10	2,67	2,40	0,16	1,03	0,93

Results and Discussion

It is well recognized (Johnson & Collins 2009) that the T1 images allow excellent depiction of both normal and abnormal anatomy, whereas the STIR sequence is better to demonstrate edema changes in the soft tissues and bones.

Injured Area and Volume Evolution:

Figures 2A-D exemplify the Axial T1 images taken for one DFU patient at four different moments in time, which depict gradual changes in lesion morphology, until ulcer closing at the end of treatment. The position reproducibility guarantees reliable calculations of the area and volume variations as a function of treatment time, shown in Figures 2E and 2F. The lesion

area changed from 1.23 cm² before the treatment to 0.23 cm² on week 17 (81% reduction). In the same period, the lesion volume changed from 2.82 cm³ to 0.38 cm³ (86% reduction).

For the ten DFU patients, initial ulcer mean volume was 6.7 cm³ (range 2.1 to 25.2 cm³). Mean lesion volume reduction after the mean treatment period of 8.7 weeks was 1.3 cm³ (0.2 to 4.7 cm³), representing an 80.6% reduction.

As a consequence of the wound complex morphology, area control is not a sufficient criterion to follow up of the healing process and volume measurements provide important additional information.

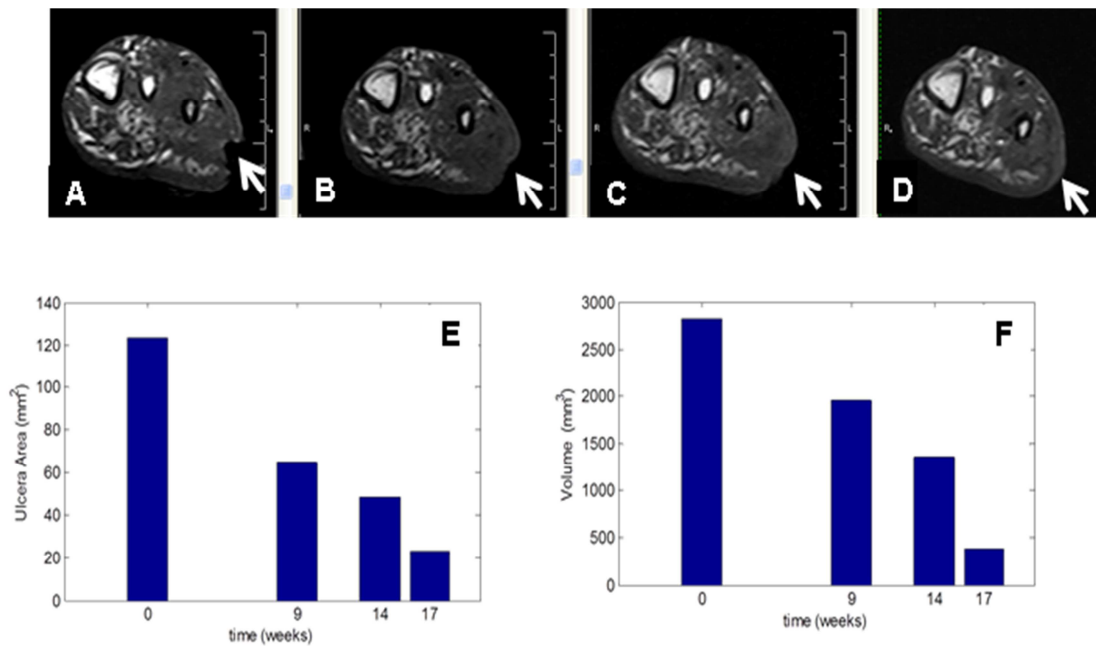


Fig. 2: Axial T1 Images (A-D) and MRI Lesion Area and Volume Measurements (E and F, Respectively) for One Treated DFU Patient. A: before Treatment; B-D: 9, 14, and 17 Weeks of Treatment, Respectively.

Figures 3A-C depict 3D MRI ulcer evolution reconstructions produced from the STIR set of images of one DFU patient. Figure 3A is the lesion before treatment, and 3B and 3C, correspond to weeks 6 and 10 after treatment, respectively. The red dot lines indicate the regions containing the lesion. The area between the red and blue dot

lines in Figure 3B denotes the granulation and re-epithelization process, as consequence of the action of EGF in the wound. Figure 3C shows the ulcer entire cicatrization area, with the hyper intense region inside the blue line being related with the new epithelium.

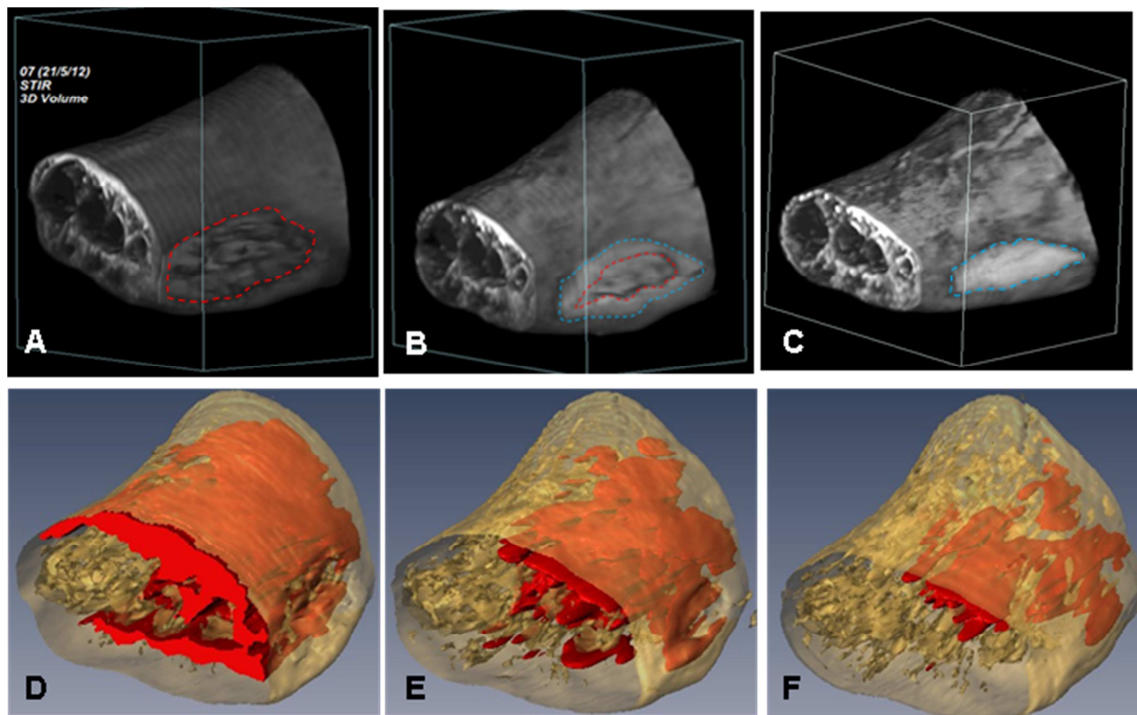


Fig. 3: MRI STIR 3D Reconstruction. Wound (A-C) and Edema (D-F) Changes during EGF Treatment: A and D: before Treatment; B and E: Week 6 after Treatment; C and F: Week 10 after Treatment. The Calculated Edema Volumes were 137 cm³ (D), 94 cm³ (E) and 54 cm³ (F).

Edema Volume Evolution: The connection between the state of the DFU and edema is still a problem not fully understood or sufficiently appreciated. For this reason, MRI evaluation of DFU and edema during the treatment is a matter of high importance.

Figures 3D-F exemplify a 3D MRI reconstruction of the edema volume evolution as a function of the treatment time, produced from the STIR set of images of the same DFU patient referred to in Figures 3A-C. The edema volumes before treatment (Figure 3D), and after weeks 6 and 10 of treatment (Figures 3E and 3F, respectively) are shown in red. Initial volume was 137 cm³, decreasing to 54 cm³ at week 10 (61% reduction).

For the ten patients studied, the original ulcer edema mean volume was 133.3 cm³ (69 to 193 cm³), decreasing to a mean value of 70 cm³ (range 54 to 93 cm³) after the mean treatment period of 8.7 weeks. This represents a 52.5% reduction.

The edema modification can be evaluated and followed up in the surroundings of the lesion, or in another specific zone. Overall, after the lesion has been totally closed, the edema is still decreasing. Residual edema could be associated with the lesion recurrence reported in some patients (Lopez-Saura et al., 2013).

ADC Changes: DWI is a powerful method where the images somehow reflect the intensity and direction of the water molecules movement in each microzone of the object under examination. The H₂O diffusion at each voxel depends on bio-structural factors; *e.g.* cell membranes and density such as the fibroblast, organelles, and macromolecules like collagen and tissue micro-architecture. Indeed, ADC values calculated from images provide some evidence related to the tissue texture in each micro region (Khoo et al., 2011).

ADC was evaluated for all DFU patients as a function of the treatment time. Figure 4 shows three ADC time dependent curves: a

healthy foot (in red), DFU patients (in blue), and the free water ADC (in the top, in black), as control.

These plots demonstrate that DFU ADC curves show a trend toward the healthy foot values, with treatment time. Regardless of ADC complex dependence on different tissue characteristics, if the

measurements are performed under identical conditions (foot position, MRI pulse sequence, slice orientation, etc.) we could hypothesize that changes in the relative ADC values in the lesion environment during the healing process are connected to the tissue texture differences, and others physio-pathological characteristics, such as edema.

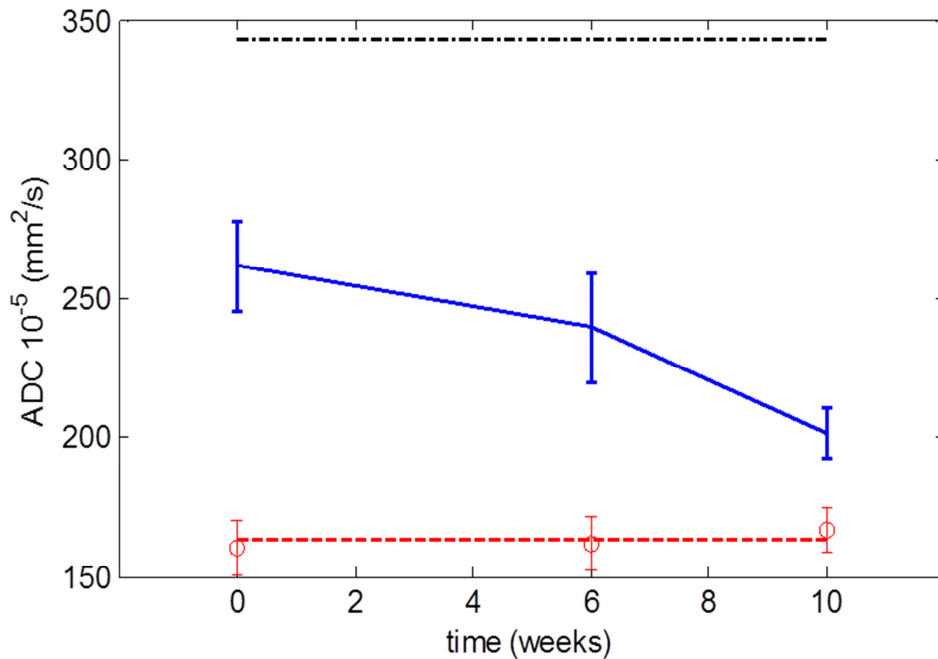


Fig. 4: Calculated ADC as a Function of Treatment Time (in Weeks). The ADC of a Healthy Foot is Shown in Red. The Blue Line is the ADC of the DFU, and the ADC Value of the Free Water is Shown in Black.

An exhaustive data evaluation can contribute to understand the healing process with the course of treatment. Perhaps the ADC values reported in this work are the foremost for DFU patients presented. Nonetheless, this is a complex question therefore further research continues to appraise more deeply the connection among the ADC variation and the lesion physiopathology.

In Vivo Metabolite MRS: As an example, Figure 5 shows the ¹H MRS from a healthy

volunteer (A) and a DFU patient (B), obtained under the same conditions. Two conspicuous lines are observed, corresponding to lipids (Lip, the largest) and Creatine (Cr). The amplitude of the lines for the healthy foot is at least two times that of the DFU; the Lip/Cr amplitude ratio varies from healthy to diseased foot as well.

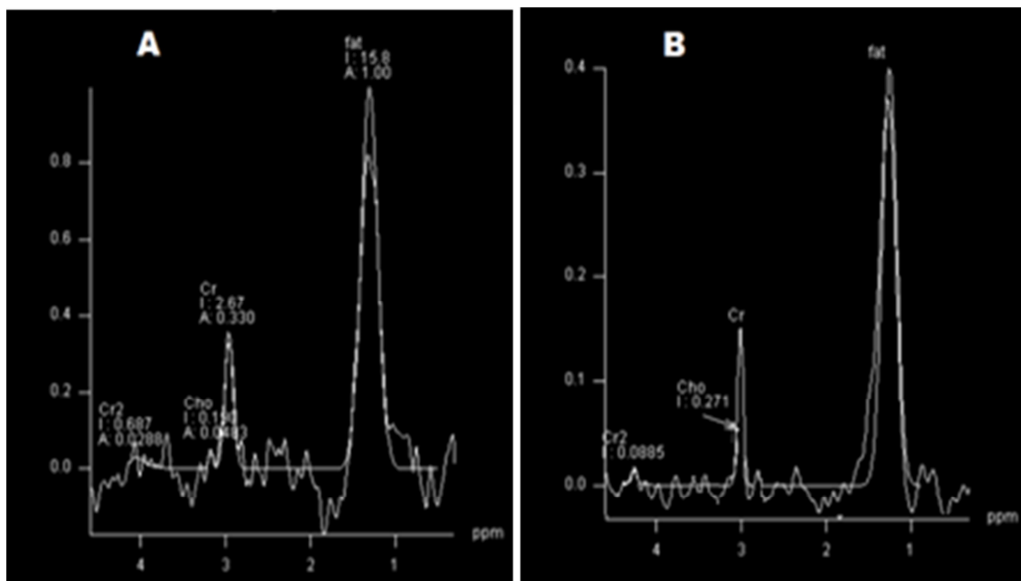


Fig. 5: MRS of a Single Voxel (1 cm³) in a Healthy Volunteer (A) and in a DFU Patient (B). Two Lines are Visible in Both Spectra, a Larger One Corresponding to Lipids and a Smaller One for Creatine. In A, the Amplitudes are Approximately Two-Fold Larger than in B.

Although the large voxel size (1 cm³) does not allow a definitive conclusion, the results suggest that the spectral lines amplitude might be used as a marker for foot status. In fact, previous research (Suzuki et al., 2000) has already pointed to the amplitude of Lip, Cr and water lines as possible indicators for the muscular atrophy associated with the DF neuropathic state. Comparing the amplitude of MRS lines during the treatment may provide valuable complementary information. More detailed studies are ongoing to address this question.

Conclusion

MRI and MRS provide new quantitative evidence related to the healing process in DFU under EGF treatment. Decrease in injured area and volume, reduction of edema volume, and trend seen in ulcer ADC towards values seen in healthy zones, are all useful to characterize the DF response to therapy, and could be used in practice as status and evolution markers. Comparing the amplitude of MRS lines during treatment may also provide additional

metabolic information. Further investigations should continue to evaluate all these aspects more deeply.

This MRI/MRS reported procedure might be also useful for evolution studies of others pedal disorders, for example, those associated with wounds, inflammatory processes and tissues changes.

Acknowledgments

The authors wish to thank all volunteers and patients. Also thanks to the CIGB and the CIMEQ for supporting this work. Thanks to Professor Jorge Gavilondo for the discussion.

Author Disclosure Statement

I confirm that this manuscript is not under consideration for publication elsewhere. Publication is approved by all authors and by the responsible authorities where the work was carried out. There are not any kind of conflict between authors and institutions. I affirm that all the ethics precepts was been taking into account. No competing financial interests exist.

References

- Acosta, J. B., Savigne, W., Valdez, C., Franco, N., Alba, J. S., del Rio, A., Lopez-Saura, P., Guillen, G., Lopez, E., Herrera, L. & Fernandez-Montequin, J. (2006). "Epidermal Growth Factor Intralesional Infiltrations Can Prevent Amputation in Patients with Advanced Diabetic Foot Wounds," *International Wound Journal*, 3(3):232-239.
- Andreassen, C. S., Jakobsen, J., Ringgaard, S., Ejksjaer, N. & Andersen, H. (2009). "Accelerated Atrophy of Lower Leg and Foot Muscles a Follow-Up Study of Long-Term Diabetic Polyneuropathy Using Magnetic Resonance Imaging (MRI)," *Diabetologia*, 52 (1):1182-1191.
- Freund, W., Weber, F., Billich, C. & Schuetz, U. H. (2012). "The Foot in Multistage Ultra-Marathon Runners: Experience in a Cohort Study of 22 Participants of the Trans Europe Footrace Project with Mobile MRI," *BMJ Open*, 2:e001118.
- Frykberg, R. G., Zgonis, T., Armstrong, D. G., Driver, V. R., Giurini, J. M., Kravitz, S. R., Landsman, A. S., Lavery, L. A., Christopher Moore, J., Schuberth, J. M., Wukich, D. K., Andersen, C. & Vanore, J. V. (2006). "Diabetic Foot Disorders: A Clinical Practice Guideline," *Journal of Foot and Ankle Surgery*, 45 (5): S1-S66.
- Johnson, P. W., Collins, M. S. & Wenger, D. E. (2009). "Diagnostic Utility of T1-Weighted MRI Characteristics in Evaluation of Osteomyelitis of the Foot," *American Journal of Roentgenology*, 192 (1):96-100.
- Khoo, M. M. Y., Tyler, P. A., Saifuddin, A. & Padhani, A. R. (2011). "Diffusion-Weighted Imaging (DWI) in Musculoskeletal MRI: A Critical Review," *Skeletal Radiology*, 40 (6):665-681.
- López-Saura, P. A., Yera-Alos, I. B., Valenzuela-Silva, C., González-Díaz, O., del Río-Martín A., Berlanga-Acosta, J., Fernández-Montequín, J. I., Acevedo-Castro, B., López-Mola, E. & Herrera-Martínez, L. (2013). "Medical Practice Confirms Clinical Trial Results of the Use of Intralesional Human Recombinant Epidermal Growth Factor in Advanced Diabetic Foot Ulcers," *Advances in Pharmacoepidemiology & Drug Safety*; 2 (2):1000128.
- Mohan, V. (2013). "Has the Time Come for Routine Imaging Studies in Diabetics?," *Diabetes Technology and Therapeutics*, 15(5): 349.
- Sanverdi, S. E., Ergen, F. B. & Oznur A. (2012). "Current Challenges in Imaging of Thediabetic Foot," *Diabetic foot & Ankle*, 3.
- Schmid, M. R., Hodler, J., Vienne, P., Binkert, C. A. & Zanetti, M. (2002). "Bone Marrow Abnormalities of Foot and Ankle: STIR versus T1-Weighted Contrast Enhanced Fat-Suppressed Spin-Echo MR Imaging," *Radiology*, 224 (2):463-469.
- Suzuki, E., Kashiwagi, A., Hidaka, H., Maegawa, H., Nishio, Y., Kojima, H., Haneda, M., Yasuda, H., Morikawa, S., Inubushi, T. & Kikkawa, R. (2000). "1H- and 31P-Magnetic Resonance Spectroscopy and Imaging as a New Diagnostic Tool to Evaluate Neuropathic Foot Ulcers in Type II Diabetic Patients," *Diabetologia*, 43 (2):165-172.
- Vartanians, V. M., Karchmer, A. W., Giurini, J. M. & Rosenthal, D. I. (2009). "Is there a Role for Imaging in the Management of Patients with Diabetic Foot?," *Skeletal Radiology*, 38 (7):633-636.